



Universidad de Oviedo



ASTURIAS  
CAMPUS DE EXCELENCIA  
INTERNACIONAL

**UNIVERSIDAD DE OVIEDO**  
**MÁSTER UNIVERSITARIO DE ORTODONCIA Y ORTOPEDIA DENTOFACIAL**

**RISK FACTORS FOR ROOT RESORPTION IN THE  
ORTHODONTIC TREATMENT**

**Claudia Suárez Calleja**

**Trabajo Fin de Máster**  
**Mayo 2015**





Universidad de Oviedo



ASTURIAS  
CAMPUS DE EXCELENCIA  
INTERNACIONAL

**UNIVERSIDAD DE OVIEDO**  
**MÁSTER UNIVERSITARIO DE ORTODONCIA Y ORTOPEDIA DENTOFACIAL**

**RISK FACTORS FOR ROOT RESORPTION IN THE  
ORTHODONTIC TREATMENT**

**Trabajo Fin de Máster**

**Claudia Suárez Calleja**

**Tutor: Dr. Félix de Carlos Villafranca**







Universidad de Oviedo

ACRONYMS:

CBCT: Cone-beam computed tomography

PDL: Periodontal Ligament

RR: Root resorption

TAs: Thermoplastic Appliances





Universidad de Oviedo

## ABSTRACT

Root resorption is a common and undesirable iatrogenic consequence associated to the orthodontic treatment that can lead to permanent loss of dental structure. It occurs in 100% of orthodontic patients but normally is repaired being clinically not detectable. The damage must be considerable to be radiographically diagnosed. The diagnosis of root resorption is usually based on routine radiographic examination with periapical and panoramic radiographs, they are the most used radiographic methods although they are limited as they produce a bidimensional image of a tridimensional structure. The superimposition of structures makes this method inaccurate for the correct diagnosis, being a cone-beam computed tomography more useful in this matter. Fortunately, truly root resorption that threatens the longevity of the tooth, affect the functional capacity of the teeth and that compromise the outcome of a successful treatment is unusual. It remains unclear the process why root resorption occurs exactly. The etiologic factors are complex and multifactorial, and are generally divided into treatment-related factors which means factors derived from the treatment and the mechanic such as magnitude, duration, type of force and type of movement, and patient-related factors or intrinsic factors such as age, gender, tooth type, root shape, systemic factors, genetic and individual variability. Many reports in the literature report that patients undergoing orthodontic treatment are more likely to have severe apical root resorption, although is not considered the main risk factor. The purpose of this review is to identify the main risk factors and the potential relationship between root resorption and orthodontic treatment in order to be able to prevent severe lesions from happening. We have searched in the literature for different factors considered to enhance root resorption and reviewed the possible link to this lesion and the active orthodontic treatment.

Key words: “Root resorption”, “risk factors”, “intrusion”, “orthodontic movement”, “root resorption diagnosis”





Universidad de Oviedo

## RESUMEN

La reabsorción radicular es una consecuencia iatrogénica, común e indeseable, asociada al tratamiento de ortodoncia que puede dar lugar a pérdida permanente de la estructura dental. Ocurre en el 100% de los pacientes de ortodoncia pero normalmente se repara antes de que sea clínicamente detectable. Para diagnosticarlo radiográficamente el daño debe ser considerable. El diagnóstico de la reabsorción radicular se basa normalmente en exámenes radiográficos rutinarios con periapicales y radiografías panorámicas, aunque estos métodos tienen sus limitaciones ya que producen una imagen bidimensional de una estructura en tres dimensiones. La superposición de estructuras hace que este método sea impreciso para el correcto diagnóstico, siendo la tomografía computarizada cone-beam más útil en estos casos. Afortunadamente, una verdadera reabsorción radicular que ponga en peligro la supervivencia del diente, afecte su capacidad funcional y comprometa el éxito en el tratamiento ortodóncico no es frecuente. No se conoce con claridad el proceso por el cual ocurre la reabsorción radicular. Los factores etiológicos son complejos y multifactoriales, y los podemos dividir en factores relacionados al tratamiento, es decir, derivados del tratamiento y la mecánica como magnitud, duración, tipo de fuerza, y tipo de movimiento, y factores en relación al paciente o factores intrínsecos como edad, sexo, tipo de diente afectado, morfología radicular, factores sistémicos, genética y variabilidad individual. Aunque no es considerado el principal factor de riesgo, la literatura recoge numerosos artículos donde se confirma que los pacientes en tratamiento de ortodoncia tienen más probabilidades de desarrollar lesiones severas de reabsorción radicular. El propósito de esta revisión es identificar los principales factores de riesgo y la potencial relación entre reabsorción radicular y el tratamiento de ortodoncia con el fin de poder prevenir la aparición de lesiones de reabsorción severas. Para llevar a cabo esta revisión, se han buscado en la literatura diferentes factores que son considerados potencialmente de riesgo para el desarrollo de reabsorción radicular, y se ha revisado la posible relación con estas lesiones así como con el tratamiento de ortodoncia activo.

Palabras clave: “Reabsorción radicular”, “factores de riesgo”, “intrusión”, “retrusión”, “movimiento ortodóncico”, “diagnóstico de reabsorción radicular”-



Universidad de Oviedo

## INDEX

<b>1. Introduction</b> .....	3
1.2 Etiology .....	4
1.3 Diagnóstico .....	10
1.4 Pronostic .....	11
<b>2. Objectives</b> .....	17
<b>3. Material and Methods</b> .....	21
<b>4. Discussion</b> .....	25
4.1. Treatment related factors .....	26
4.1.1. Magnitude of force .....	26
4.1.2. Duration of force .....	27
4.1.3. Type of force .....	30
4.1.3.1. Instrusion vs Extrusion .....	30
4.1.3.2. Sagital movement .....	33
4.1.3.3. Root torque .....	34
4.1.4. Treatment time .....	34



Universidad de Oviedo

4.2. Patient related factors .....	35
4.2.1. Age .....	35
4.2.2. Gender.....	35
4.2.3. Dental and root anomalies .....	37
4.2.4. Teeth affected .....	42
4.2.5. Genetic and individual susceptibility .....	44
4.2.6. Tooth trauma .....	46
<b>5. Final considerations .....</b>	<b>49</b>
<b>6. Bibliography .....</b>	<b>53</b>

# 1. INTRODUCTION





## 1. INTRODUCTION

Root resorption (RR) is a common and undesirable iatrogenic consequence associated to the orthodontic treatment that can cause permanent loss of dental structure<sup>1-18</sup>. Damage of two tooth structures is involved, cementum and dentin, and it can be reversible or irreversible; it can be repaired by the cementoblast activity or stay resorbed. RR occurs during treatment when forces exceed the resistance and reparative capacity of the periapical tissues.

It occurs in 100% of orthodontic patients, although of low intensity<sup>19</sup>. Fortunately, truly root resorption that threatens the long life of the tooth, affects the functional capacity of the teeth and that compromise the goal of successful treatment is unusual<sup>1,9,20-23</sup>. The average amount of resorption of examined anterior teeth is less than 1.5 mm during comprehensive treatment<sup>24</sup> but it could vary from 0.20 mm to a maximum of 3 mm<sup>5</sup>. Parker and Harris<sup>11</sup>, found 1.4 mm of RR on his sample.

Severe root resorption is defined as the resorption of the root that exceeds 4 mm or one-third of the original root length, is seen in 1% to 5% of teeth<sup>6,18,25</sup>. Artun et al,<sup>20</sup> reported that according to Mirabella et al in 1995, 5% of adults and Linge et al in 1983, 2 % of adolescents are likely to have at least 1 tooth with resorption of more than 5 mm during active treatment.

The literature contains many reports of clinical and in vitro studies of root resorption but there are two main impediments to prevent root resorption: First of all, when the periodontium is under compression root apices are prone to resorption, teeth can not move through the bone without causing some odontoclasia, and secondly the fact of not having an exact guideline to predict which patients will develop large resorptions and which will experience little under the same treatment characteristics<sup>11</sup>. As most patients develop not much resorption, the aesthetic and functional benefits of treatment exceed the minor iatrogenic consequence.



## ETIOLOGY

At present, it is unknown how orthodontic treatment influences RR exactly. Although there are many meticulous investigations in the literature, no single factor or group of factors that directly causes RR have been identified<sup>27</sup>. The etiologic factors are complex and multifactorial<sup>5,16,24,25,25,28,29</sup>. It is still a challenge for researchers to identify all factors that interfere with the biological system and cause resorption<sup>23</sup>. It results from a combination of factors related to the treatment such as magnitude<sup>3,8,15,26,27,30-33</sup>, duration<sup>27,31,32,34-38</sup>, type of force, type of movement<sup>(2,3,4,6,8,30,31,35,39)</sup>, treatment time<sup>1,2,3,5,6,8,20,21,30,39</sup> and factors related to the patient such as sex<sup>5,7,11,21,40</sup>, age<sup>2,5,24</sup>, dental and root anomalies<sup>1,19,20,24,25,26,41,42</sup>, individual biological variability<sup>4,7,20,26</sup> and genetic predisposition<sup>4,25,26</sup>.

It has been reported that there is familial clustering for RR but no clear patterns of inheritance has been identified. There is significant variation in RR susceptibility among patients<sup>7</sup> and genetic factors could explain approximately 64% of the RR variation in humans. It has also been found susceptibility variations in relation to the ethnic background, being Asian patients less prone to suffer from resorption than white or Hispanic patients<sup>7,24</sup>.

There is currently no mechanism for determining which patients will respond to orthodontic tooth movement with apical root resorption<sup>12,15,28</sup>.

The literature reports that patients undergoing orthodontic treatment are more likely to have severe apical root resorption<sup>1-6,8,11,14,20,21,25-27,30,31,43,44</sup> although is not considered the main risk factor. When a tooth is moved orthodontically, remodelling changes occur in dental and paradental tissues such as dental pulp, periodontal ligament, alveolar bone and gingiva. The extension of all changes that take place, macroscopic or microscopic, will depend on the different magnitude, frequency and duration of the mechanical force<sup>35</sup>. The concentration of orthodontic forces on the root, especially in the apex, can cause biological changes in the cementum and the periodontal ligament, resulting in root resorption<sup>27,30,39</sup>. Some studies with a finite model found greater concentrations of stress on the root from intrusion forces<sup>11</sup>.



Orthodontic treatment requires resorption and apposition of the adjacent bone to root surface of the teeth in compressed and stretched sides respectively, to allow the movement. The area of the bone that opposes to the direction of the movement needs to be resorbed in order to allow the root to move. Therefore, some bone resorption is required in the so-called compression area. On the opposite site, the bone must follow the tooth trying to keep the periodontal thickness intact. New layers of bone will be placed on the tooth surface of the alveolar bone in the so-called tension area. There is then, some bone resorption in the compression area and some bone apposition in the tension area<sup>51,58</sup>. To achieve this outcome, only small amount of force, 20 to 150 g per tooth, might be required. Chan and Darendeliev<sup>33</sup> reported that already in 1932, Schwarz stated that the optimal force for tooth movement should be within the levels of capillary pressure. This is 20 to 26g cm<sup>2</sup> of force per root surface area. It has also been noted that if orthodontic force levels exceed this, periodontal ischemia occurs, and root resorption can result.

There are two types of resorptions that can occur when a force is applied to the tooth: direct or frontal resorption and indirect or undermining resorption.

#### DIRECT OR FRONTAL BONE RESORPTION:

The periodontal ligament is located between two hard areas, cementum and alveolar bone. Under light physiologic compressive forces, the blood vessel area only partially occluded. No hyalinization of the PDL (Periodontal Ligament) occurs, an osteoclastic activity starts and this will resorb the bone alveolar wall that opposes to the tooth movement. This is the direct or frontal bone resorption on the compression area<sup>51,58</sup>.

#### INDIRECT OR UNDERMINING BONE RESORPTION:

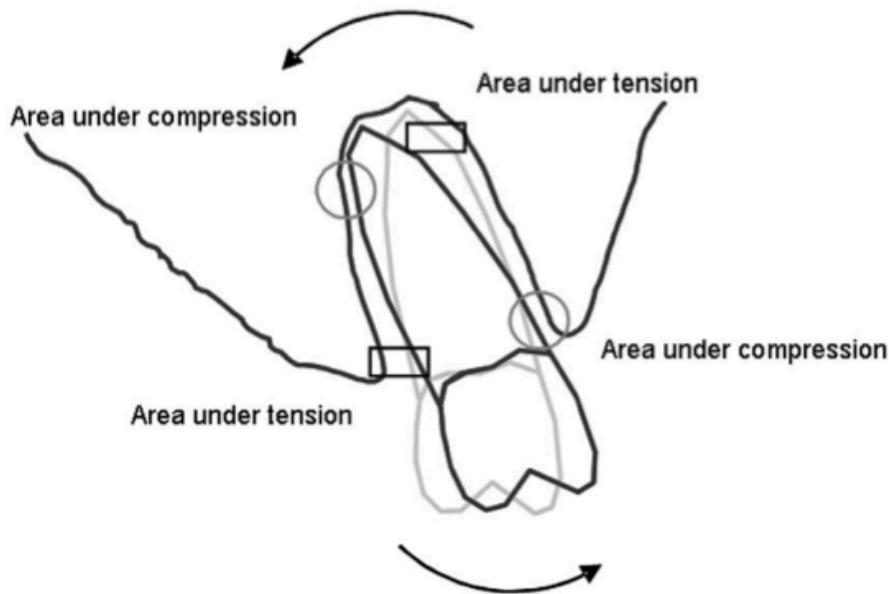
With sufficiently high level of compressive force, the blood vessels in the PDL become totally occluded and the vital activity of the PDL on that zone stops<sup>45</sup>. This phenomenon impedes the direct resorption of the bone, and therefore another mechanisms to resorb the bone that opposes to the movement need to take place. This results in histological





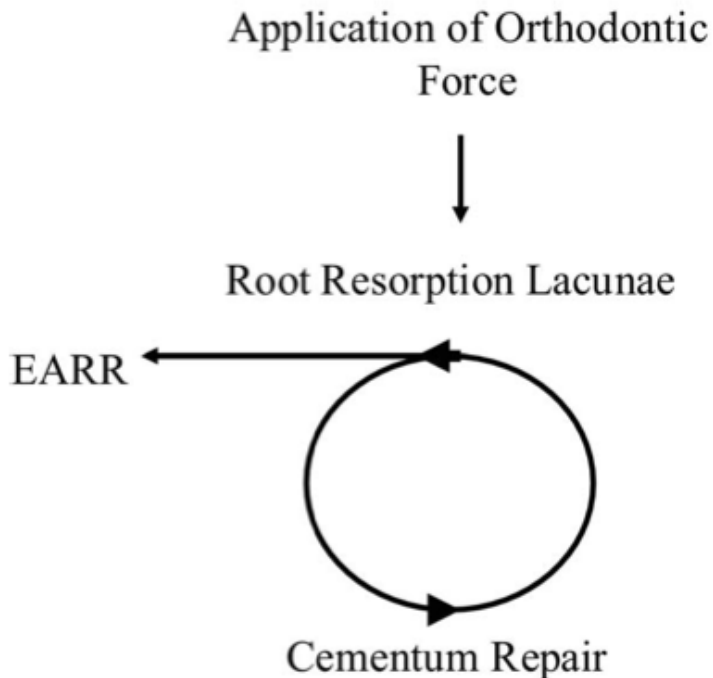
changes in the periodontum known as hyalinization. Osteoclasts to destroy and resorb the bone to allow the movement appear coming from distant areas. This is contrary to the direct bone resorption where the osteoclasts come from the periodontal space. If the force is too heavy that jeopardizes the arrival of the osteoclasts to the area to resorb the bone, the root is resorbed instead. This means irreversible loss of cementum, and sometimes dentin<sup>33</sup>. This allows to explain why a strong and continuous orthodontic force can lead to severe root resorption. It is impossible, with the available instrumentation, to measure exactly how much force is applied to roots under treatment<sup>35</sup>, and even maximising the control of the orthodontic forces, it is difficult to avoid some hyalinised areas in the periodontal ligament.

Root cementum is a relatively independent tissue and, different to the bone, is not involved in metabolic processes, such as calcium homeostasis. For many years it was believed that the cementum did not suffer from the same remodelling processes than the bone. However, certain changes in cementum resemble those that take place in bone. When an orthodontic force is applied, the cementum suffers from the same kind of attack and it is also repaired, therefore root resorption occurs on all areas of the root under compression. As with osteoid, cementoid tends to decrease in thickness on the side of compression. Resorption lesions of the cementum after orthodontic tooth movement appear mainly in regions of compression and not so commonly in regions of tension<sup>32-34</sup> (Figure 1). It has been documented that root resorption is frequently preceded by hyalinization of the periodontal ligament<sup>51,58</sup>.



**Figure 1.** Diagram showing areas under compression or tension (Taken from Chan and Darendeliler , 2006)

During the remodelling process of the hyalinised zone, the adjacent cementum to the necrotic areas of the periodontal ligament is attacked by the odontoclasts when repairing the ligament. As a side effect of the cellular activity during the removal of the necrotic PDL tissue, the cementoid layer of the root and the bone gets unprotected in certain areas that can readily be attacked by resorptive cells. Normally, cementum does not undergo appreciable resorption. It is removed from the tooth surface while the active force is acting, and afterwards, during the inactive periods, it is restored. However, orthodontic force (increased magnitude or duration) can sometimes induce excessive resorption of the root cementum, reaching and exposing the dentin underlying the damaged cementum (Figure 2). This fact enhances the probability of odontoclasts attack exceeding the reparative capacity and therefore resulting in RR. When the resorptive lesion extends beyond the cementum layer and into the dentin, it is irreversible<sup>12,32</sup>



**Figure 2.** Representation of the balance between RR and cementum repair. When RR exceeds the reparative capacity of the cementum, the RR is seen radiographically. (Taken from Abass et al, 2008).

The remodelling of the root is characteristic of the orthodontic movement, and permanent loss of the root surface will only take place if the repair does not restore the cementum that has been previously resorbed.

The repair of the damaged root will not be possible if the aggression causes important defects at the apex, which can even get separated from the root. Whenever part of the apex separates completely from the root, it is resorbed and cannot be replaced<sup>51,58</sup>.

It is generally accepted that some type of irreversible damage must occur to the cemental layer before true resorption occurs. For this to be seen radiographically of course the damage must be considerable<sup>23</sup>.



Approximately 75-85 per cent is repaired completely with secondary cementum<sup>7,13</sup>. Signs of repair in the examined tissues, cementum and PDL of intruded teeth for 4 weeks with constant force were observed by Faltin et al, in 2001. This process occurs first in the periphery of the hyalinised zones and also close to the areas of the reabsorbed cementum<sup>27</sup>. When the orthodontic force is applied for short periods of time, the RR that occurs, can be histologically diagnosed but not radiographically visible.

The sensitivity of the apex to intrusion, extrusion or torquing displacements suggests that there is some component of the root apex that has a lower threshold for irreversible change than other parts of the root<sup>21</sup>. Also, the severe resorption of the cementum in the apical third may be due to fewer Sharpey's fibre (less barrier), greater blood supply (clast cells), higher metabolism in the adjacent PDL, and its structure resembling the alveolar bone. The characteristics of the intrusive movement tend not to overload the cervical area of the root, moreover the presence of a greater number of Sharpey's fibres in the cervical third, may represent a barrier against resorption. The exact distribution of capillary blood pressure along the periodontal ligament is unknown but might also contribute to the differences<sup>27,29</sup>. In 2006, Harris et al, observed by microcomputed tomography scan x-ray system that the apical thirds of all surfaces had more root resorption crater<sup>15</sup>. Faltin et al, in 2001 designed an histological study of the cementum and periodontal ligament (PDL) changes after continuous intrusion in humans. Numerous and severe signs of degeneration in fibroblasts, cementoblasts, and cementocytes were observed in all intruded teeth, and more frequently in the apical third in proportion to the magnitude of force. Intrusive force has been associated with increased early resorptive cellular activity. Since the apical third is the zone of main pressure during intrusion movements, it is understandable that mechanical stress may be responsible for the vascular flow alteration that provokes cellular degeneration<sup>27</sup>.

oo



## DIAGNOSIS

The detection of RR is usually based on routine radiographs, but also can be done through light microscope, scanning electron microscope, and microcomputed tomography<sup>26,32</sup>. Clinically the most common system to diagnose this clinical condition is the radiographic examination, such as periapical or panoramic radiographs. And although they are important as a diagnostic tool, these methods are limited as they produce bidimensional images of a tridimensional structure, thus root resorption seems not completely assessable on two-dimensional images, the images reflect the superimposition of the whole root structure and can lead to underestimation of the extent of apical root resorption.<sup>4,9,22,32,34</sup>. This phenomenon makes the quantitative value of radiographs questionable and geometrically inaccurate being a cone-beam computed tomography (CBCT) more useful in this matter<sup>9,10,34</sup>. This method eliminates the superimposition of structures and show different levels of resorption on the labial and lingual surfaces. The superimposition causes the extent of the lesion to be determined by the longest surface, therefore hiding the most resorbed areas of the root. It also has the advantage of a much lower radiation to the patient when compared with conventional computed tomography<sup>9,24,41,46</sup>. Conventional CT scanning has a significant advantage over 2D radiography in the clinical detection and quantification of root resorption, but its high cost and high radiation exposure to the patient limit its clinical use<sup>32</sup>. Chan and Darendellier<sup>33</sup> found tridimensional volumetric evaluation of RR craters to be a viable alternative with a high level of accuracy and repeatability.

Normally, although CBCT is the most accurate diagnostic tool, periapical radiographs are the method of choice for monitoring the progress of resorption lesions during orthodontic treatment<sup>10</sup>. But as soon as moderate root resorption lesions are diagnosed, CBCT scans should be taken to evaluate the real extent of the lesions for prevention of severe lesions<sup>9</sup>.

In 2001, Sameshina and Asgarifar, evaluated whether there is one type of x-ray film (periapical vs panoramic) more accurate than other in the pretreatment evaluation of root shape and the post treatment computation of root resorption. It has been observed



that periapical films have been found to be superior to panoramic images for fine detail of alveolar bone and root and less distortion. If initial and final panoramic films are used, the amount of root resorption will be exaggerated by 20% or more. Lower incisors are especially vulnerable to this distortion<sup>3</sup>.

## PRONOSTIC

Root resorption stops once the active orthodontic appliances are removed. However, if resorptive lesion occurs following orthodontic treatment, and root length is less than 9mm in maxillary incisors, there is a risk of tooth mobility. The risk decreases if the length is  $> 9\text{mm}$ <sup>18</sup>. But even extensive RR does not usually affect the function and long-term longevity of the teeth.

An average maxillary central incisor with no bone loss but root shortened by 5mm will still have 75% of its periodontal attachment remaining<sup>6</sup>.

It is generally agreed that 3 mm of RR is equivalent to 1 mm of crestal bone loss<sup>25</sup>, therefore the diagnosis of teeth with severe root resorption after orthodontic treatment should be followed up clinically and radiographically by the periodontist or general dentist until the resorption has stabilized<sup>26</sup>. It is recommended to monitor these patients same way as when there is some vertical bone loss that has compromised crown-root proportion to control of occlusal trauma that may cause RR progression and for periodontal monitoring to avoid further crestal bone loss<sup>21,22</sup>.

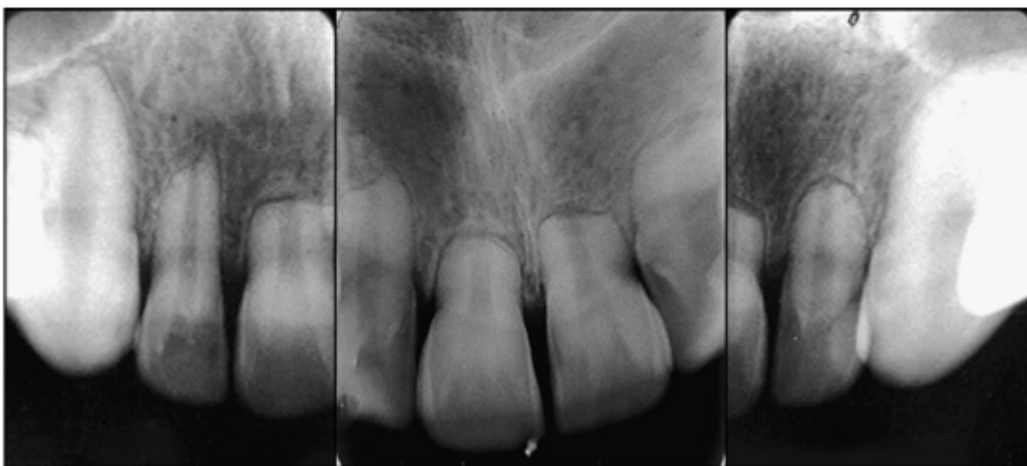There is some evidence that to interrupt the treatment for 4-6 months when RR is found, (inactive phase, with a passive archwire) decreases further RR before restarting the case. The inclusion of rest periods, with no application of force, in the treatment of patients with a tendency towards root resorption is important. After a few days of inactive periods, the repair of the resorption lesions with deposits of cementum is



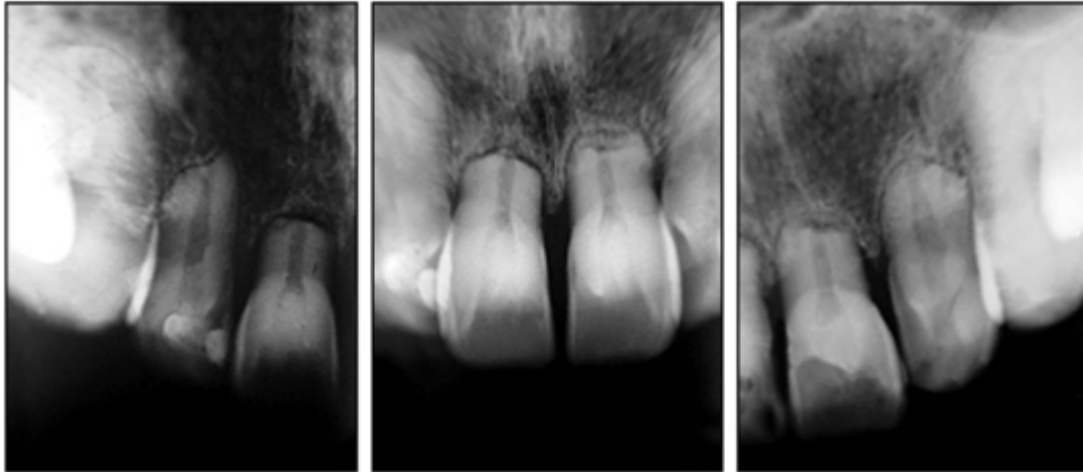
observed. In severe cases the treatment must be ceased and appliances removed<sup>6,7,10,18,21,22</sup>.

A retrospective analysis of patients who had experienced RR (root lengths 5.5-18.1mm), recalled 5 to 15 years after treatment, found that no teeth had mobility scores greater than 1 on Miller's index, and no teeth had been lost<sup>22</sup>.

Another recent case from Marques et al, 2011<sup>18</sup>, illustrates the occurrence of severe root resorption associated with orthodontic treatment and its evolution 25 years after completion of treatment. The patient was a 10-year-old male with biprotrusion, the treatment plan was to treat him with headgear and fixed appliances but due to the lack of cooperation, it was decided to extract the 4 first premolars and to carry on with fixed braces and the use of class II elastic bands. The patient was on treatment for approximately 9 years. The periapical radiographs taken at the end of treatment showed severe root resorption of the incisors (Figure 3). A follow-up 25 years after completing the treatment showed a stable situation where the resorptive lesion did not show any significant progression (Figure 4) and the patient had a healthy periodontal status. The long duration of treatment, the retraction mechanics used, and the prolonged use of intermaxillary elastic bands may have contributed significantly to the severe root resorption in this patient.



*Figure 3, Situation at the end of the treatment (Taken from Marques et al, 2011)*



*Figure 4, Follow up 25 years after treatment completed (Taken from Marques et al, 2011).*

This resorption could have been easily diagnosed in periapical radiographs of the anterior teeth in the first 6 months after beginning of treatment<sup>18</sup>. The early detection of root resorption during orthodontic treatment is essential to identify teeth with a risk of severe resorption<sup>9</sup>.

An important factor on this case is that the patient reported healthy oral hygiene habits over the years and frequent visits to a dentist for prophylactic procedures<sup>18</sup>.

In the recent literature, it has been of interest to study pharmacologic methods that could control the severity of resorption<sup>47, 48</sup>. It is commonly known the chemical qualities of the fluoride as a preventive factor in dentistry. Its properties lead to some changes in the molecular level forming a structure more stable considered more resistant to demineralization<sup>47, 48</sup>. Karadeniz et al<sup>47</sup> and Gonzales et al in 2011<sup>48</sup> have hypothesized that this fact may have an influence to reduce root resorption by increasing hardness of cementum. It has been evaluated if high and low levels of fluoride intake from birth in drinking water affect orthodontic root resorption, and as a result it would be less severe. They have both observed reduced volume of resorption craters, being the reduction more significant with heavy forces. The duration of the fluoride administration also seems to affect the severity of the resorptive lesion. Gonzales et al<sup>48</sup>, also pointed out





Universidad de Oviedo

## INTRODUCTION

the fact of amount of tooth movement being decreased if fluoride intakes increased. It has not been discovered yet a pharmacologic therapy to control the root resorption without interfering in the tooth movement<sup>47</sup>

## 2. OBJECTIVES





## 2. OBJECTIVES

- To clarify the relationship between root resorption and orthodontics
- In-depth analysis of the prevalence and amount of root resorption induced by orthodontic treatment.
- To identify the main risk factors.



### 3. MATERIAL AND METHODS





### 3. MATERIAL AND METHODS

This review is based on the search of articles related to the risk factors for root resorption in the orthodontic treatment. The search and literature review of the main scientist articles has been done using the databases: PubMed, Library of Medicine of University of Oviedo, Cochrane, Scielo, and several journals such as American Journal of Orthodontics, European Journal of Orthodontics, Angle Orthodontics, Journal Clinical of Orthodontics.

The search has been limited to articles within the last 5 years but also old publications have been included in order to help to achieve the objective of this study as they are considered as a reference in the literature.

No restrictions have been made on the language.

Key words: “Root resorption”, “risk factors”, “intrusion”, “orthodontic movement”, “root resorption diagnosis”





## 4. DISCUSSION





#### 4. DISCUSSION

Apical root resorption caused by orthodontic tooth movement is an undesirable incident, which is impossible to avoid and difficult to predict and repair<sup>6,10,23,47</sup>.

The main difficulties in studying root resorption are the infrequency of severe shortening and the many possible factors that can be associated with it. The risk factors for orthodontically induced RR have been extensively investigated and are generally divided into treatment-related factors which means factors derived from the treatment and the mechanic used<sup>5,8,25,26</sup> such as magnitude, duration, type of force and type of movement, and patient-related factors or intrinsic factors such as age, gender<sup>5,8</sup>, tooth type, root shape<sup>1,5,19,41,42</sup>, systemic factors, genetic and individual variability<sup>7,12,13,40</sup>.

Many recent studies aimed to clarify the causal relationship between application of the force, dental movement and root resorption<sup>43</sup>. Among dental movements, incisor intrusion and anterior retraction seem to cause the greatest resorption during orthodontic treatment<sup>30</sup>, but the complex combination of mechanical tooth movements, such as extrusion, intrusion, translation, tipping, torqueing, and rotations produced by the many orthodontic appliances makes it difficult to identify specific tooth movement likely to increase the risk of RR.

Most research correlated resorption with intrusive forces, retraction and with different types of techniques but did not identify specific movements<sup>30</sup>. Some other authors did not find any correlation with the treatment mechanic, being slot size and archwire type not important,<sup>6,8,11,20,24,26,42</sup> and others agree that the biomechanics used is a risk factor but is not the sole part that can interfere with the biological system and cause root resorption<sup>15</sup>.

Parker and Harris<sup>11</sup>, found that vertical apical movement, vertical incisal movement, and incisor proclination changes were consistently predictive of RR, and Motokawa et al<sup>6</sup> referred that the type of tooth movement such as tipping, bodily movement, and torque might be a risk factor.



## 1. TREATMENT RELATED FACTORS

### 1.1 MAGNITUDE OF FORCE

#### STRONG FORCES VS LIGHT FORCES

Root resorption associated with orthodontic treatment is more apparent in subjects where the applied forces are strong and of extended duration<sup>8,11,15,26-29,31,34,35</sup>. Many studies in animals and humans have agreed that force magnitude is directly correlated with the severity of RR<sup>6,8,15,26,27,29,31,32,33,47</sup>.

To produce an adequate biological response in the periodontium, light forces are preferable because they induce to frontal resorption of the bone. When heavy forces are used, the tissue repair process is compromised, as the rate of gap development is more rapid<sup>27,32,33</sup>. Heavy forces in both compression and tension areas produce significantly more RR than in regions under light compression and light tension forces as often causes necrosis (hyalinization) of the ligament, resulting so in root resorption<sup>35</sup>. In Faltin et al's study, the teeth intruded with 50cN presented resorptive and degenerative lesions that were less intense and extensive than those intruded with higher magnitude forces (100cN). This agrees with other findings demonstrating that severity of resorption is clearly dependent on the magnitude of the force applied<sup>11,15,25,27,32,33,39</sup>.

It has been suggested that, if the force to produce orthodontic movement is greater than the partial pressure of the periodontal capillaries (26g/cm<sup>2</sup>), periodontal ischemia will occur and lead to root resorption<sup>34</sup>.

With the exception of a study by Chan and Darendeliler<sup>33</sup>, who found the mean volume of resorption craters in the light-force group not significant, all teeth experiencing orthodontic movement had significantly more RR than the control teeth, where no force was applied<sup>11,15,25,32,39</sup>. However, Chan and Darendeliler<sup>33</sup>, agree with other authors that heavy-force group show greater mean volume of the resorption craters than in the light-force group, (11.59 times, significant). Parker et al<sup>11</sup> and Costopoulos et al<sup>39</sup>, showed on



his histologic studies that force magnitude was related to root resorption, greater lesions appeared when heavier forces were applied to intruded teeth. Harris et al<sup>49</sup>, also found that the volume of RR craters after intrusion was directly proportional to the magnitude of the intrusive force. Barbagallo et al<sup>32</sup>, support this concluding that heavy force produced significantly more RR (9 times greater than in the control where the teeth were not moved) than light forces (5 times greater than in the control). Also the effect of clear removable thermoplastic appliances (TAs) with light and heavy forces was compared; the sample consisted of 54 premolars in 27 patients and observed that TAs have similar effect on root cementum as light (25g) orthodontic forces with fixed appliances.

Zahrowski et al<sup>25</sup>, on his systematic review of literature from 1950 to 2008, state that heavy forces are particularly harmful, especially during intrusive movements.

## 1.2 DURATION OF FORCE

### INTERMITTENT VS CONTINUOUS FORCES

It has also been discussed whether continuous or intermittent orthodontic forces produce more root resorption. Studies in the literature have investigated and compared the relationship between intermittent and continuous forces and root resorption and a pause in the tooth movement seems to allow the damaged cementum to heal, therefore discontinuous forces would cause less root resorption. If the pressure is high, ischemia will occur and leads to root resorption, when it decreases below the periodontal threshold, root resorption ceases<sup>27,32,34</sup>. If continuous force is used, the ideal level should be lower than the recommended for intermittent force<sup>27</sup>.

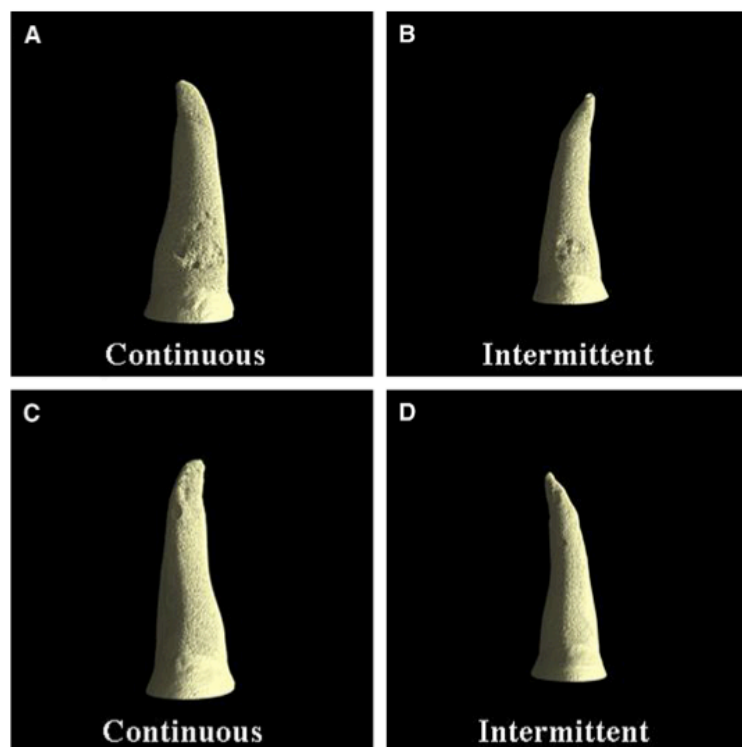
Clinical experience suggests that successful tooth movement requires a threshold of force duration of about 6 hours per day<sup>35</sup>.

Most contemporary fixed orthodontic appliances use light continuous forces as mechano-therapy<sup>8,26</sup>. However, a continuous force can slow down quickly and thus be interrupted after a short period of time. It seems to be more biologically favourable this type of force, that starts in a continuous way and then becomes interrupted. In these



cases, hyalinised areas may appear in compression zones of the PDL, but as soon as the necrotic tissue is removed and the tooth moved, the force decreases rapidly. Finally, between appliance activations, there is a chance for the tissue to reorganize and to calcify forming a new osteoid layer. This is called the rest period, during this time the archwire retains its passivity for a short time what induces cell proliferation for further tissues changes when the appliance is activated again<sup>35</sup>. A continuous interrupted force may be contemplated as the most favourable option, especially to reduce the prevalence of root resorption<sup>34-36</sup>.

Comparing intermittent to continuous forces, Ballard et al<sup>34</sup>, have studied the response of 16 maxillary first premolars with same level and same duration of force. The premolars have been later analysed with microcomputed-tomography scan system, concluding that discontinuous forces cause less root resorption than continuous forces.(Figure 5)



**Figure 5**, Root resorption craters in a 3D image; **A**, continuous force, buccal view; **B**, continuous force, lingual view; **C**, intermittent force, buccal view; **D**, intermittent fore, lingual view (Taken from Ballard et al, 2009).



Cuoghi et al<sup>37</sup> and Aras et al<sup>49</sup>, found also higher prevalence of root resorption when using continuous force.

There are some other studies that report little or no resorption using continuous forces for intrusion using for example miniscrews as fixed anchorage<sup>31,38</sup>.

During the past few years, different proposals to slow down the orthodontic force have been studied, this includes drugs such as bisphosphonate or nonsteroidal anti-inflammatories and hormones<sup>50,51,53,56</sup>. Liu et al<sup>50</sup> found that the local administration of the bisphosphonate Clodronate inhibited root resorption; Sirisoontorn<sup>54</sup> proved that the administration of zoledronic acid, an innovative bisphosphonate, to osteoporotic rats inhibits the excessive tooth movement and also reduces the risk of severe root resorption induced by orthodontic treatment; Loberg et al<sup>51</sup>, Poumpros et al<sup>56</sup> and Shirazi et al<sup>53</sup> concluded that thyroxine administration seemed to increase the rate of alveolar bone resorption, thus, indirectly decreasing root resorption.

Another research of Bialy et al<sup>55</sup> studied the effect of low-intensity pulsed ultrasound (LIPUS) on healing process of orthodontically induced root resorption in humans. LIPUS can enhance healing of traumatized connective tissues and stimulate dental tissue formation. On his study, continuous forces were applied to twelve premolars during 4 weeks, and short periods of LIPUS were used on half on the premolars. Then they were studied by scanning electron microscopy and histologically. The outcomes were promising showing reduction of resorption and acceleration in healing of the resorbed tooth surface by hypercementosis in the LIPUS-exposed premolars.





### 1.3 TYPE OF MOVEMENT

#### 1.3.1 INTRUSION VS EXTRUSION

Intrusion is an aggressive movement to periodontal structures<sup>27</sup>, and therefore intrusive forces are considered one of the most predictive risk factor for root resorption because root shape concentrates pressure at the conical apex<sup>2,3,4,11,15,23,26,27,30,31,35,39</sup>. This concentration of forces, particularly in the apical third, can cause biological changes in the cementum and the periodontal ligament, resulting in root resorption<sup>27</sup>. Erkan et al, in 2007 also studied the gingival response to intrusion. These authors failed to find any significant change in the width of attached and keratinized gingivae if adequate plaque control is maintained, confirming that gingiva moved in the same direction with the tooth<sup>56</sup>.


Although many authors agree that intrusion and retraction forces are strongly related to root resorption<sup>2,3,4,7,11,26,27,30,38</sup>, some controversy exists about incisor intrusion being a major factor contributing to RR<sup>2,21,31,38</sup>. Numerous variables can influence the results, due to the complexity in differentiating which factor is involved in root resorption.

In this way, Carrillo et al, in 2007 studied the effect of intrusion using mini-screw implants as anchorage. Radiographically, there was little or no evidence of root resorption associated with the intrusive movement. In addition, the resorption lesion found was 0.1mm or less in all cases and there was no clear pattern with respect to the forces, the teeth or the area of resorption (apical or interradicular). These authors assume that root resorption probably occurs at the apex and interradicular areas of the intruded teeth, but it is undetectable radiographically and usually repairs after force is stopped<sup>31</sup>.

Weltman et al<sup>26</sup>, Faltin et al<sup>27</sup> and Zahrowski et al<sup>25</sup> agreed that comprehensive orthodontic treatment coupled with heavy or intrusive forces might increase the incidence and intensity of RR.



Han et al in 2005<sup>4</sup>, studied eighteen first premolars from nine patients stating that all intruded teeth showed signs of resorption. Substantial differences in the extent and depth of the root resorption were observed between the intruded and extruded teeth, as shown in figure 6, concluding that the intrusion causes about four times more root resorption than extrusion. RR from extrusive force was not significantly different from the control group, where the premolars with no pre-existing RR were extracted as part of the treatment plan before active orthodontic treatment started. These authors also mentioned a possible individual susceptibility to RR, therefore this means that extrusive movement is still at risk on those patients susceptible to RR.



**Figure 6**, Indicators showing resorptive lesions in (a) Control root. (b) An intruded root. (c) An extruded root. The magnification is 15x. Bar = one mm (Taken from Han, 2005).



Parker and Harris<sup>11</sup> examined 110 patients treated with three different orthodontic techniques. Incisor intrusion together with lingual root torque was the strongest predictors of apical root resorption, and there was no statistical difference between techniques. This is in agreement with Deguchi et al<sup>38</sup> who did not find any difference in the mechanics used to intrude the incisors, and using miniscrews does not seem to increase the rate of RR.

Martins et al<sup>30</sup> studied 2 groups of 28 patients each, with similar mean age and treatment duration, the first group presented with an increased overjet and deep overbite and the second with an increased overjet and normal overbite. Generally, there are 3 ways to correct overbite: absolute intrusion of the incisors, relative intrusion of the incisors, and extrusion of the posterior teeth<sup>38</sup>. Patients with a deep bite treated with intrusion mechanics had greater resorption than patients with a normal overbite treated with anterior retraction without intrusion. The initial overbite severity had a positive statistically significant correlation with root resorption, which is in agreement with some other research in the literature with specific studies of the effects of intrusive mechanics demonstrating that intrusion can be considered a predictive factor for root resorption<sup>2,3,4,11,15,23,26,30</sup>. On Chiqueto et al's<sup>3</sup> research, there is also a positive statistically significant correlation of root resorption with the amount of deepbite correction, but not with the overjet correction. Due to the parallelism between the amounts of overbite and overjet correction, it is probable that the most important factor associated to root resorption is the direction rather than the amount of tooth movement<sup>23</sup>.



### 1.3.2 SAGITAL MOVEMENTS / AMOUNT OF MOVEMENT

Many authors support that the distance the teeth are moved through the bone influences the amount of RR, therefore the greater the tooth movement, the more apical resorption<sup>1,5,6,11,20,21,30,43,44</sup>.

Cases requiring premolar extractions experience more resorption than those that need less retraction of the maxillary incisors<sup>1,5,6,16,20,21</sup>. Motokawa et al in 2012<sup>6</sup>, Lee et al in 1999<sup>1</sup>, and Mohandesan et al in 2007<sup>8</sup>, found significantly greater prevalence of severe RR in extraction than in non-extraction groups. Extractions cases generally require larger tooth movement and apical displacement to correct malocclusions.

Sameshima et al<sup>21,24</sup> and Maués et al<sup>16</sup>, found the displacement of the root apex to be significant, but only in the horizontal direction, that is the overjet. No correlation between the amount of overbite present at the beginning of treatment and the amount of resorption, in particular, neither open bite nor deepbite cases had more root resorption.

Regarding the open bite, Motokawa et al, 2013<sup>10</sup> had as purpose on their study to clarify the possible relationship between root resorption and this malocclusion. One hundred and eleven patients were studied and divided into non-open bite and open bite groups. It was found that the prevalence of root resorption was higher in the open bite group than in the non-open bite group, especially in anterior and premolar teeth. It may be assumed that hypofunctional teeth in open bite cases might undergo root resorption more frequently due to the lack of external stimuli.

Brin et al<sup>44</sup>, agree with Sameshina et al<sup>21,24</sup> and Maués et al<sup>16</sup>, in the significant correlation between apical root resorption and overjet, and Rakhshan et al<sup>5</sup>, did not find either any correlation of root resorption with overbite. These findings, are in contrast with other studies such as Chiqueto et al<sup>3</sup>, these authors found only vertical displacement of the maxillary central incisor apices had a positive correlation with root resorption.

Dermaut and De Munck<sup>2</sup> and Sameshima et al<sup>21</sup> did not find any association between root resorption and the distance the teeth are moved or intruded, similarly Liou and



Chang<sup>43</sup> stated that apical root resorption was not correlated to the amounts of en-masse anterior retraction, intrusion or palatal tipping.

### 1.3.3 ROOT TORQUE

When root resorption occurs and there is loss of the root length, the centre of resistance moves coronally, therefore the amount of torque on the tooth will have more effect than if the root were untouched. Giving a lingual root torque to the upper central incisors is strongly correlated to RR<sup>4,11,26,39</sup>. This is because to torque the upper central incisors lingually considerable force is required. This torquing force concentrates at the apex that is believed to be the most sensitive area to resorption<sup>11</sup>. In combination, intrusion and lingual root torque are the strongest evidence for causing RR<sup>4,11,26,39</sup>. Motokawa et al<sup>6</sup> also hypothesize that the type of tooth movement such as tipping and torque might be a risk factor.

On the contrary, Dermaut and De Munck<sup>2</sup> could not establish any relation between the amount of apical resorption and the position of the apex in relation to the palatal plane, that is to say no relation to torque.

### 1.4 TREATMENT TIME

It has been widely discussed whether treatment time enhances root resorption.

In some studies no relation could be found between the amount of resorption and the duration of the force<sup>1,2,10,28,30,44</sup>.

If patients who require greater tooth movements also require more time, the factor that predisposed to resorption is not only the treatment duration. In these cases, it is considered that the amount of tooth movement is the most important factor. Artun et al<sup>20</sup>, failed to find any significant links to treatment duration. It has been proven in Martins et al study, that two groups of patients, one with an increased overjet and deep overbite and the other one with an increased overjet and normal overbite, with similar treatment times, presented different severity of root resorption. It is sensible to think that the factors affecting treatment duration were similar and did not influence the



difference in root resorption. Therefore treatment did not have a significant correlation with resorption<sup>30</sup>.

Some other reported that the severity of the root resorption was directly correlated to duration of treatment<sup>3-6,8,11,16,21,39,57</sup>. Motokawa et al<sup>6</sup> studied 3 groups of patients divided into different subgroups depending on treatment time, prevalence of severe RR was significantly higher in the group treated for more than 30 months and therefore it was concluded that long-term orthodontic treatment increases the prevalence of RR.

The factor of time could be a total sum of all factors disposing a patient to apical root resorption during orthodontic tooth movement<sup>43</sup>. Consecutive stress on the PDL lasting for longer time could lead to more hyalinization and less repair activity in the area of compression, and therefore causing increased damage of the surface of the root<sup>8</sup>.

## 2. PATIENT RELATED FACTORS

### 2.1 AGE

Although some articles in the literature agreed that the age of the patient at the start of the treatment does not influence on RR development<sup>5,10,39,40</sup>, many research have concluded that RR occur less in young children. The chances of resorption increase when orthodontic treatment takes place after the root is completed<sup>2,16,23,25,28</sup>.

Shaw et al, in 2004 found that the mechanical stress at the apex increases with the thickness of apical cementum (Table 1), and it has been reported that the thickness of the cementum increases in a linear relationship with age<sup>23</sup>.



Apex cementum thickness ( $\mu\text{m}$ )	Stress at apex ( $\text{N}/\text{mm}^2$ )
1000	0.00625
800	0.00152
600	0.00122
400	0.00115
200	0.00088

**Table 1**, Table showing thickness of the cementum and the amount of stress at root apex (Taken from Shaw et al, 2004).

Sameshima et al, on one hand found adults significantly more susceptible to RR by as much as 0.8 mm when mandibular lower teeth were included in the study; On the other hand, reported no difference in age for maxillary anterior dentition. They have been unable to explain the reason why lower incisors were affected in adults only<sup>24</sup>.

Ren et al, demonstrated in their study in adult rats that older animals respond different to younger animals, it has been found a significant positive correlation between root resorption and the velocity, amount and duration of tooth movement in adult rats but not in younger rats. Although they still have not been able to identify the basic molecular and biological processes, age in itself represents a factor to take into account<sup>28</sup>.

## 2.2 GENDER

Although most of human and animal studies show no sex difference in RR<sup>5,7,11,21,40</sup>, Mohandesan et al<sup>8</sup> found greater incidence in females but in lateral incisors only and Abass et al<sup>7</sup> found on his study in mice, sex difference only among one specific strain, with the males being more susceptible to RR than females. This fact implies that sex difference is strain dependent and so, it is not only the sex that determines the susceptibility to RR. The genetic background could put either sex at higher risk of RR.



Being female did not significantly affect the prevalence of clinical RR, but was associated with its severity. When incisor resorption was noted in females, it occurred to a greater extent<sup>5</sup>. Parker and Harris<sup>11</sup>, did not find any correlation between RR and gender.

Mohandesan et al<sup>8</sup> found the effect of gender only for the maxillary lateral incisors, showing more RR than those of male patients.

### 2.3 DENTAL AND ROOT ANOMALIES

There have been conflicting conclusions concerning association between teeth anomalies and root resorption. Several studies have mentioned the potential relationship between the occurrence of root resorption during orthodontic treatment and abnormal dental morphology such as agenesis, short, blunt, dilacerated, pipette roots, taurodontism and invagination. (Van Parys et al, 2012<sup>41</sup> ; Lee et al, 1999<sup>1</sup>; Mavragani et al, 2006<sup>42</sup> ; Zahrowski et al, 2011<sup>25</sup> ;Weltman et al, 2010<sup>6</sup>; Artun et al, 2009<sup>20</sup>; Kamble et al, 2012<sup>19</sup>; Sameshima et al, 2001<sup>21,24</sup> ; Motokawa et al, 2013<sup>37</sup>; Brin et al, 2003<sup>42</sup>). Some of them confirm a relationship while others did not.

Sameshima et al<sup>21,24</sup>, agreed with current clinical recommendations to be careful when the case requires great amount of movement for a long time of abnormally shaped teeth. These authors used drawings with a visual scale to assess root resorption and found that abnormal root shape is a significant risk factor and dilacerated root shape (particularly maxillary lateral incisors) had the most resorption, followed by bottle-shaped and pointed teeth (Table 2). Teeth with short, blunt roots are not at increased risk of resorption.

It is believed that amount of resorption increases with tooth length and reduced with root width<sup>24</sup>.





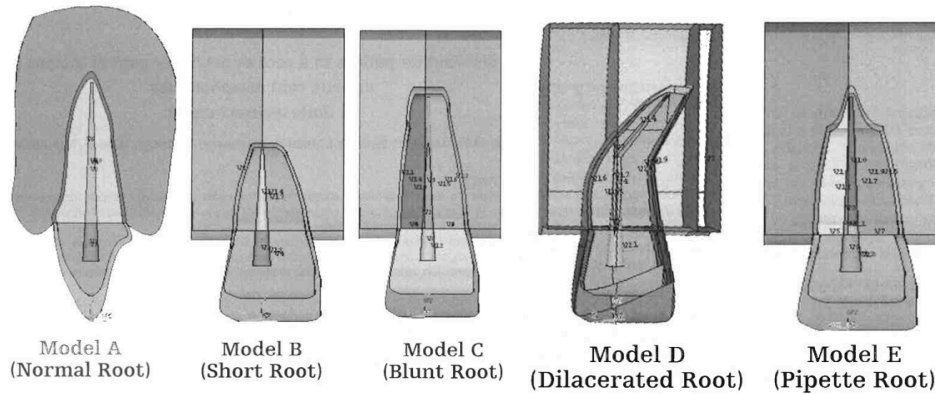
	<i>Normal (mm)</i>	<i>Blunted (mm)</i>	<i>Dilacerated (mm)</i>	<i>Pipette (mm)</i>	<i>Pointed (mm)</i>
Maxillary central incisors	1.20 ± 1.38	0.69 ± 1.24*	1.53 ± 1.08	1.58 ± 1.47 <sup>†</sup>	1.64 ± 1.59 <sup>†</sup>
Maxillary lateral incisors	1.27 ± 1.49	0.98 ± 1.22	1.58 ± 1.48 <sup>†</sup>	1.47 ± 1.20	1.39 ± 1.52
Maxillary canines	1.08 ± 1.70	1.30 ± 1.34	1.35 ± 1.63	1.56 ± 0.96	1.24 ± 1.65
Mandibular central incisors	0.66 ± 1.13	0.23 ± 1.44	0.75 ± 0.93	None	0.89 ± 1.12 <sup>†</sup>
Mandibular lateral incisors	0.80 ± 1.35	0.37 ± 1.65	1.06 ± 1.20	None	0.89 ± 1.22
Mandibular canines	0.89 ± 1.68	0.04 ± 1.23*	1.29 ± 1.42	None	1.35 ± 1.56 <sup>†</sup>

\*Significantly less resorption than the other 4 groups ( $P < .01-.001$ )

<sup>†</sup>Significantly greater resorption than the normal and blunted groups ( $P < .05-.01$ ).

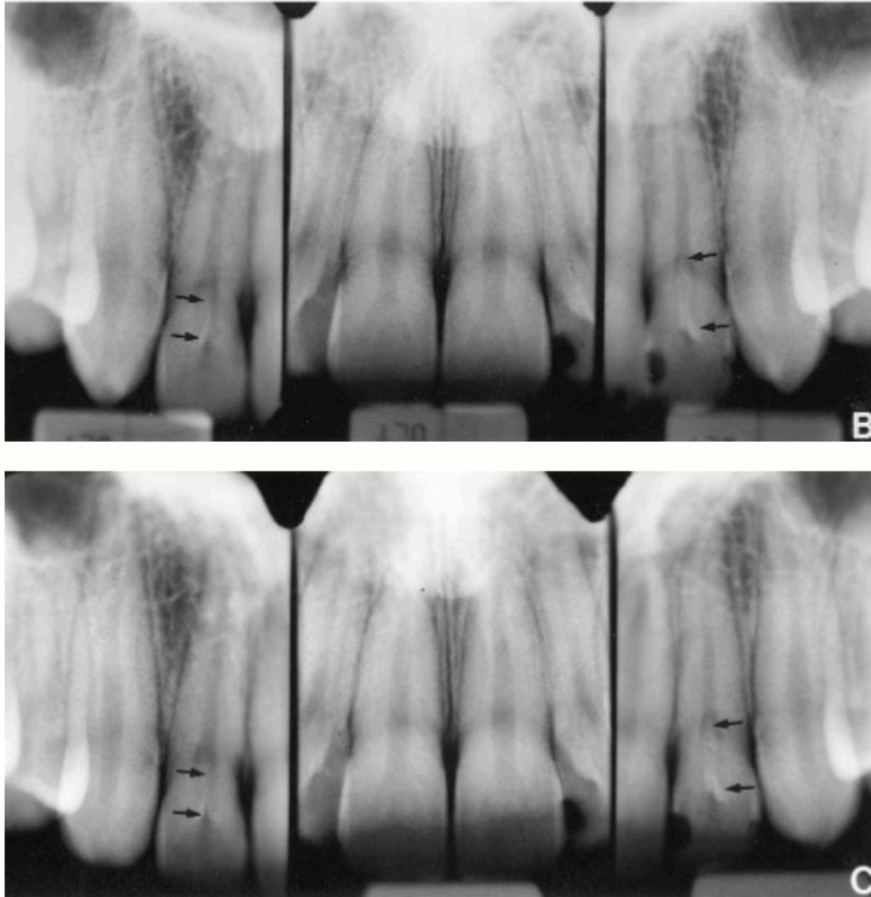
**Table 2** taken from Sameshima et al, 2001. Table showing root resorption according to location and root shape.

Kamble et al<sup>19</sup> investigated stress distribution when applying experimental orthodontic forces in different root morphologies of central maxillary incisors using the finite element model (FEM) (Figure 7). The forces that are normally used in the clinical practice such as intrusion, extrusion, tipping, rotation, and bodily movement were applied to the surface, simulating a bracket base. Model A (normal root) and C (blunt root) show no significant stress concentration at the root. In model B (short root), significant stress correlation was concentrated at the neck of the root. This finding is related to the alteration of the crown-root ratio. A decrease in the ratio of the root is said to intensify the loading on the root, resulting in significant stress. In model D (dilacerated root ape), stress was concentrated at the middle and apical regions of the root. For model E (pipette root), despite of the direction of the force application, stress was concentrated at the middle of the root. Therefore it is concluded that deviations in root shape resulted in more loading of the root, being dilacerated root morphology the most affected, followed by pipettes-shaped root.



**Figure 7.** Root morphologies used in the FEM study. (A) Normal root morphology. (B) Short root morphology. (C) Blunt root morphology. (D) Dilacerated root morphology. (E) Pipette root morphology (Taken from Kamble, 2012).

Some authors like Lee et al<sup>1</sup> do not support the hypothesis that orthodontic patients with dental anomalies are at increased risk of RR during active orthodontic therapy. 84 patients with some dental anomaly and 84 without it were compared and no differences were found in apical maxillary resorption between the patients in the two groups (Figure 8). In addition, patients with more that one anomaly did not appear to be at increased risk.



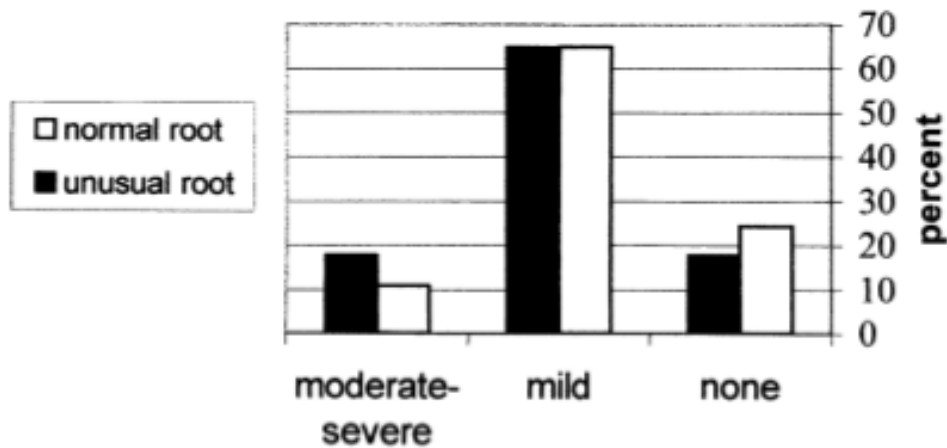
**Figure 8,** *Periapical radiographs of pretreatment (B) and posttreatment (C) of a patient in the experimental group. Minimal resorption is shown. Indicators pointing the invaginations lesions of maxillary lateral incisors (Taken from Lee, 1999).*

Dental invagination is the most prevalent dental anomaly in orthodontic patients (26.1 per cent). Mavragani et al<sup>42</sup>, similarly to Lee et al<sup>1</sup>, according to their results concluded that there is no evidence of being dental invagination a risk factor for orthodontic apical root resorption. The authors compared 49 orthodontic patients with at least 1 maxillary incisor invagination with 42 patients who had no dental invaginations. The statistical analysis showed no significant difference in the severity of apical root resorption between invaginated and non-invaginated incisors. An interesting finding was that invaginated and non-invaginated incisors. An interesting finding was that invaginated



teeth more often presented deviated root anatomy than non-invaginated teeth. Root malformation has been considered a risk factor for orthodontic apical root resorption<sup>19,24</sup>.

Brin et al<sup>44</sup>, could not prove that teeth having unusual root morphology were more at greater risk of having moderate to severe root resorption than those with normal root forms, these teeth were only slightly more likely to have moderate to severe RR (Figure 9).



**Figure 9**, Relation between root resorption and root morphology (Taken from Brin et al, 2003).

Van Parys et al, 2012<sup>41</sup> after assessing dental anomalies, dental agenesis and root resorption in 88 subjects, were unable to confirm such relationship. It could not be proven if this is due to an absence of relationship or to the limitations of their study.

Other studies have also stated that it seems not to exist direct proof to explain why an abnormal root shape would resorb more easily. The atypical process that caused the abnormal shape in the first place is a strong possibility. If the cementum and dentin are



affected during root formation, the capacity of the cementum and dentin to resist resorption in situations where there is an excess of pressure is reduced. A genetic factor is also possible but unproven; disruption of the path of eruption is another probable cause<sup>19,24</sup>.

## 2.4 TEETH AFFECTED

A literature search regarding tooth vulnerability to root resorption found agreement among many authors. Regardless of genetic or treatment-related factors, it is remarked that in terms of severity the most frequently affected teeth are the maxillary lateral and central incisors, it remains unclear why this is the case<sup>2,5,8,9,11,14,16,22,23,25,26,40,42,43,57,59</sup>.

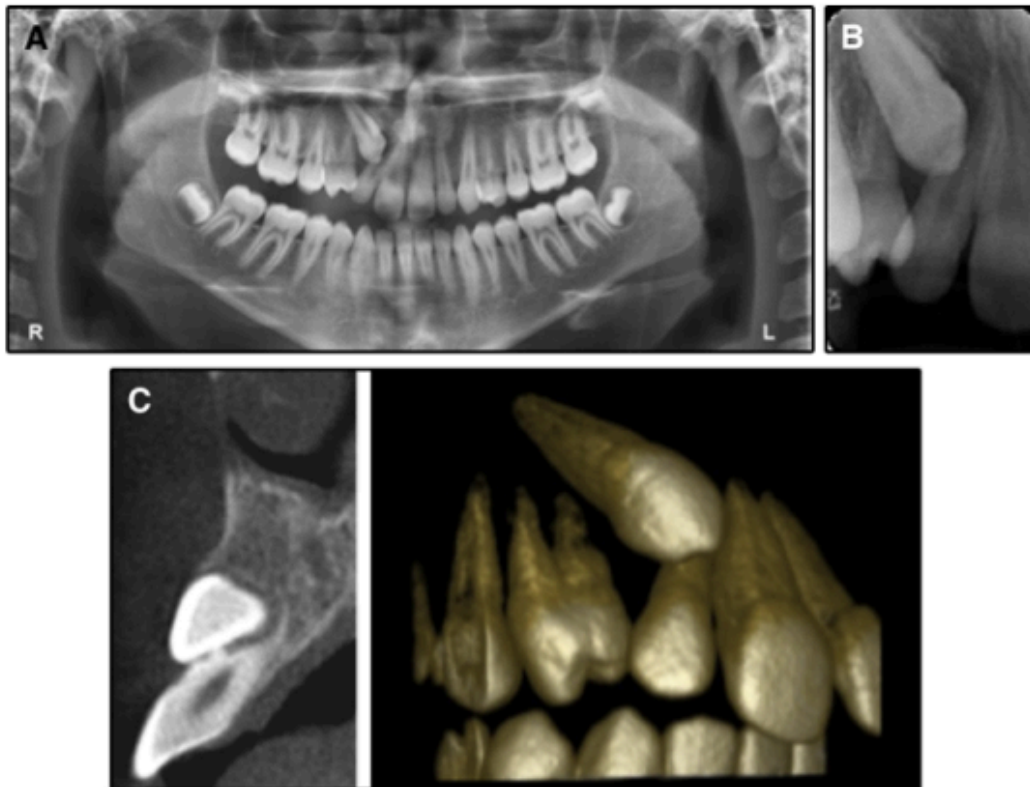
Al-Qawasami et al<sup>12</sup> stated that a mutation on certain gen explains part of this variability in susceptibility of maxillary incisors. Parker et al<sup>11</sup> and Chiqueto et al<sup>3</sup>, found that RR is most common on maxillary incisors partly due to the fact that these teeth often undergo more displacement than other teeth during extraction treatment. It seems to be related to a multifactorial phenomenon associated to morphological characteristics including apical curvatures, different root shapes and root surface areas. When applying an orthodontic force on all teeth, a tooth with smaller root surface area resists a relatively higher pressure<sup>5</sup>.

Sameshima et al<sup>24,58</sup>, Mavragani et al<sup>42</sup>, Brin et al<sup>44</sup>, and Liu and Chang<sup>43</sup> found that among the incisors the most resorbed tooth was the maxillary lateral incisor for both adults and children, followed by maxillary central incisor. Liu and Chang<sup>43</sup> explain that this could be due to the appliances and mechanics used, because of the way they were placed, the force directed to the lateral incisors would be heavier than to the maxillary central incisors. Another explanation is that lateral incisors are by nature more vulnerable than maxillary central incisors, these teeth present with highest percentages of abnormal root shapes, development anomalies including dents invaginatus, and



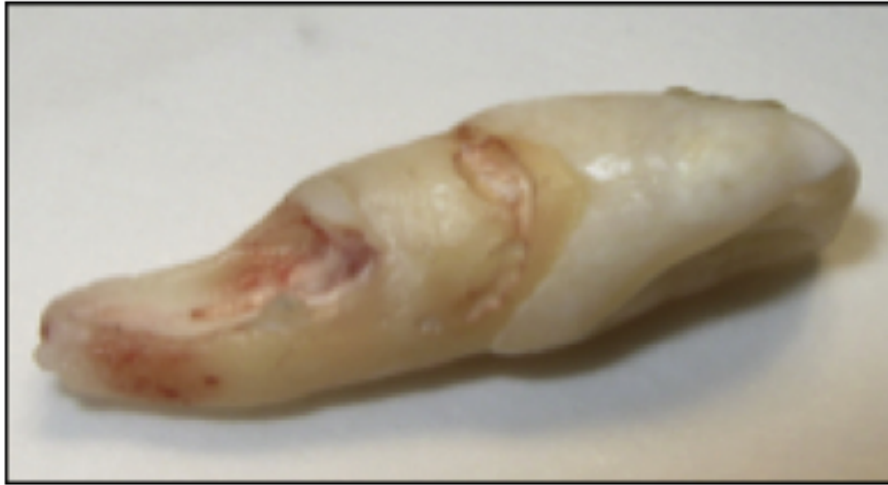maxillary lateral incisors are the third most commonly missing tooth after third molars and lower second premolars<sup>24</sup>.

A very recent report of Chaushu et al<sup>59</sup>, found that severe root resorption in maxillary incisors can be also associated to impacted maxillary canines. Lateral incisors were more often affected than central incisors. The risk of severe root resorption associated to impacted canines is increased in females, with enlarged dental follicles and anomalous lateral incisors (Figure 10 and 11).



**Figure 10**, Lateral incisors resorbed by an impacted canine in 14-year-old-boy.

*A*, panoramic view; *B*, periapical view; *C*, transaxial and 3-dimensional CBCT views (Taken from Chaushu et al, 2015).



**Figure 11**, Resorptive lesion in a lateral incisors caused by an impacted canine (Taken from Chaushu et al, 2015).

Artun el al<sup>20</sup>, failed to find this difference between central and lateral incisor regarding the amount of resorption. These authors studied maxillary incisors root resorption analysing amount of resorption before treatment, 6 and 12 months after brackets placement and post treatment, concluding that the risk of resorption increases when it is already present at the early treatment stages. This may be a helpful tool to identify patients at risk of severe resorption.

## 2.5 GENETIC AND INDIVIDUAL SUSCEPTIBILITY

There is considerable individual variability in the susceptibility to RR and differences in individual genetic predisposition that may explain a large extent of the variation in



orthodontic root resorption<sup>4,7,40</sup>. Although environmental factors related to the treatment play a role in the development of RR, it can not fully explain the differences in susceptibility<sup>7,12</sup>. Han et al<sup>4</sup> demonstrated that the amount of root resorption of the intruded and extruded teeth was highly correlated. This implies that there is an individual susceptibility for root resorption.

Artun et al<sup>20</sup> suggested that major variation in orthodontic root resorption can be explained by differences in individual predisposition and it should be considered as an etiologic factor. This agrees with other heritability investigations in humans that showed that genetic risk factors could explain approximately 64% of the variability of RR associated with orthodontic treatment<sup>7</sup>. We could then think that there is a complex combination of both genetic and environmental factors where both play roles.

RR appearance in relation to orthodontic treatment varies between people and between different teeth in the same person: there may be just a few teeth with severe resorption<sup>22</sup>. However, if genetic were considered to be the responsible for the individual predisposition to RR, a similar reaction to the resorption in all teeth would be expected. Sehr et al<sup>40</sup> on their human research studied different malocclusions where all upper incisors are moved. So, if genetic predisposition plays a major role, it is expected that all incisors react similarly during the orthodontic treatment. However, most of the patients had only one affected tooth, while the other incisors had much less RR. No more than 12.5% of the patients presented four incisors severely affected by RR, therefore it was concluded that local rather than genetic or systematic factors have more influence in the development of severe root resorption. Ren et al in 2007, also stated that due to the large interindividual differences revealed in groups of animals with a similar or homogenous genetic background, RR cannot be exclusively attributed to genetic factors<sup>28</sup>.

Contrary to this tendency to think that local causes rather than genetic factors enhance the risk of RR, different studies in animals and human have pointed various genes that may be potentially linked to the development of severe root resorption, these are: IL-1A (interleukin-1 $\alpha$ ), IL-1B (interleukin-1  $\beta$ ), TNF-  $\alpha$  (tumor necrosis factor-  $\alpha$ ), TNFRSF11A [receptor activator of nuclear factor-kappa B (RANK)] and TNFSF17



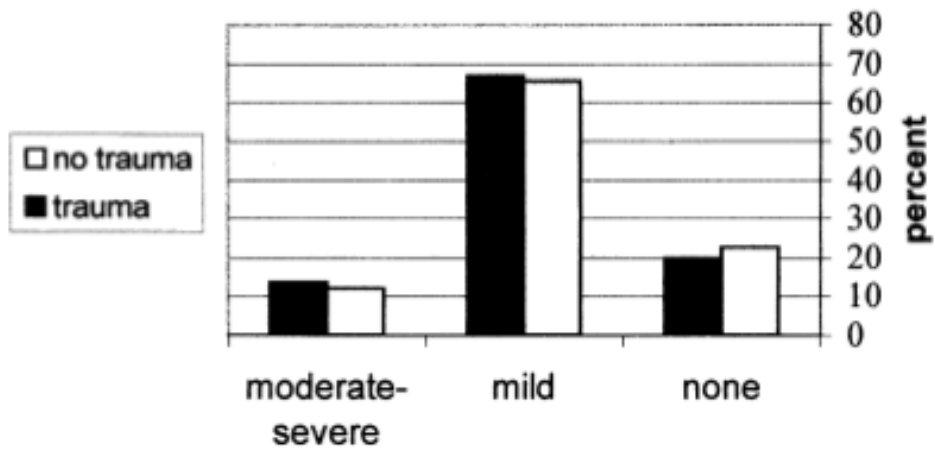


(non-specific alkaline phosphatase)<sup>12,13,14,60,61,62</sup>. According to Al-Qawasami et al<sup>12</sup>, an IL-1B mutation, explains 15% of RR's variation of maxillary incisors. Homozygous for this allele have a 5.6 times increased risk of RR greater than 2 mm as compared with heterozygotes. The data of Hartsfield et al<sup>62</sup>, indicate that there must be other genes that influence RR associated with orthodontic treatment, since approximately half of the variation in RR is influenced by genetic factors, and variation at IL-1B accounts for only 15 per cent of the phenotypic variation.

As current evidence shows the importance of genetic susceptibility to RR, it may be sensible to carry out a routine test or to design a diagnostic tool to identify patients at increase risk, in this way the clinician would be able to estimate the risk of RR<sup>6</sup>.

## 2.6 DENTAL TRAUMA

Traditionally, it has been claimed that all teeth with a previous history of trauma are more susceptible to RR than healthy teeth<sup>6</sup>. However, more recent investigations seem not to agree with this<sup>25,57,63</sup>. Brin et al<sup>57</sup>, and Mandall et al<sup>63</sup>, evaluated the effect of previous trauma on RR during orthodontic treatment. There seems to be consensus on that incisors with clinical signs or patient reports of trauma (but not signs of RR) had the same prevalence of moderate to severe RR as those without trauma, concluding that there is no statistically significant correlation between RR and trauma history (Figure 12). There is no much data about patients with traumatized teeth with RR before orthodontic treatment. This situation may indicate a greater chance that orthodontic movement will enhance the resorptive process.



*Figure 12, Relation between trauma and root resorption (Taken from Brin et al, 2003).*



## 5. FINAL CONSIDERATIONS





FINAL CONSIDERATIONS

1. Increased incidence and severity of RR is found in patients undergoing comprehensive orthodontic therapy.
2. Heavy and constant forces application, intrusion movements and root shape anomalies produced significantly more RR than light force application, extrusion movements and normal root shape.
3. More genetic analysis to identify areas of the DNA including genes that influence the susceptibility to RR are needed.
4. More evidence is required to determine risk factors for identifying those susceptible to RR and effective ways to decrease its severity and prevalence in orthodontic patients, as well as to develop a valid and reliable measurement method.



## 6. BIBLIOGRAPHY





1. Lee R Y, Ártun J, Alonzo T A. Are dental anomalies risk factors for apical root resorption in orthodontic patients?. *American Journal of Orthodontics and Dentofacial Orthopedics* 1999; 116: 187-195
2. Dermaut L R, De Munck A. Apical root resorption of upper incisors caused by intrusive tooth movement: A radiographic study. *American Journal of Orthodontics and Dentofacial Orthopedics* 1986; 90(4): 321-32
3. Chiqueto K, Martins R C, Janson G. Effects of accentuated and reversed curve of Spee on apical root resorption. *American Journal of Orthodontics and Dentofacial Orthopedics* 2008; 133(2): 261-268
4. Han G, Huang S, Von den Hoff J W, Zeng X, Kuijpers-Jagtman A M. Root Resorption after Orthodontic Intrusion and Extrusion: An Intraindividual Study. *Angle Orthodontist* 2005; 75(6): 912-918
5. Rakhshan V, Nazanin Nateghian N, Ordoubazari M. Risk factors associated with external apical root resorption of the maxillary incisors: a 15-year retrospective study. *Australian Orthodontic Journal* 2012; 28: 51-56
6. Motokawa M, Sasamoto T, Kaku M, Kawata T, Matsuda Y, Terao A, Tanne K. Association between root resorption incident to orthodontic treatment and treatment factors. *European Journal of Orthodontics* 2012; 34: 350-356
7. Abass S K, Hartsfield J K, Al-Qawasmi R A ,Everett E T, Foroud T M, Roberts E W. Inheritance of susceptibility to root resorption associated with orthodontic force in mice. *American Journal of Orthodontics and Dentofacial Orthopedics* 2008; 134(6): 742-750



8. Mohandesan H, Ravanmehr H, Valaei N. A radiographic analysis of external apical root resorption of maxillary incisors during active orthodontic treatment. *European Journal of Orthodontics* 2007; 29: 134-139
9. Campos M J S, Silva K S, Gravina M A, Fraga M R, Vitral R W F. Apical root resorption: The dark side of the root. *American Journal of Orthodontics and Dentofacial Orthopedics* 2013; 143(4): 492-98
10. Motokawa M, Terao A, Kaku M, Kawata T, Gonzales C, Darendeliler M A, Tanne K. Open bite as a risk factor for orthodontic root resorption. *European Journal of Orthodontics* 2013; 35: 790-795
11. Parker R J, Harris E F. Directions of orthodontic tooth movements associated with external apical root resorption of the maxillary central incisor. *American Journal of Orthodontics and Dentofacial Orthopedics* 1998; 114(6): 677-68
12. Al-Qawasmi R A, Hartsfield J K, Everett E T, Flury L, Liu L, Foroud T M, Macri J V, Roberts W E. Genetic predisposition to external apical root resorption. *American Journal of Orthodontics and Dentofacial Orthopedics* 2003; 123(3): 242-252
13. Al-Qawasmi R A, Hartsfield J K, Everett E T, Weaver M R, Foroud T M, Faust D M, Roberts W E. Root resorption associated with orthodontic force in inbred mice: genetic contributions. *European Journal of Orthodontics* 2006; 28: 13-19
14. Al-Qawasmi R A, Hartsfield J K, Everett E T, Flury L, Liu L, Foroud T M, Macri J V, Roberts W E. Genetic Predisposition to External Apical Root Resorption in Orthodontic Patients: Linkage of Chromosome-18 Marker. *Journal of Dental Research* 2003; 82(5): 356-360



15. Harris D A, Jones A S, Darendeliler M A. Physical properties of root cementum: Part 8. Volumetric analysis of root resorption craters after application of controlled intrusive light and heavy orthodontic forces: A microcomputed tomography scan study. *American Journal of Orthodontics and Dentofacial Orthopedics* 2006;130(5): 639-647
16. Maués C P R, do Nascimento R R, Vilella O V. Severe root resorption resulting from orthodontic treatment: Prevalence and risk factors. *Dental Press Journal of Orthodontics* 2015; 20(1): 52-8
17. Ajmera S, Venkatesh S, Gaveshkar S. Volumetric evaluation of root resorption during orthodontic treatment. *Journal Clinical of Orthodontics* 2014; 48(2): 113-119
18. Marques L S,Chaves K C T, Rey A C, Pereira J L, de Oliveira A Cruellas. Severe root resorption and orthodontic treatment: Clinical implications after 25 years of follow-up. *American Journal of Orthodontics* 2011; 139(4): 166-169
19. Kamble R H, Lohkare S, Hararey P V, Mundada R D. Stress distribution pattern in a root of a maxillary central incisor having various root morphologies. *Angle Orthodontist* 2012; 82(5): 799-805
20. Artun J, Hullenaar R V, Doppel D, Kuijpers-Jagtman A M. Identification of orthodontic patients at risk of severe apical root resorption. *American Journal of Orthodontics and Dentofacial Orthopedics* 2009; 135(4): 448-455
21. Sameshima T G, Sinclair M P. Predicting and preventing root resorption: Part II. Treatment factors. *American Journal of Orthodontics and Dentofacial Orthopedics* 2001; 119(5): 511-5



22. Levander E, Malmgren O. Long-term follow up of maxillary incisors with severe apical root resorption. *European Journal of Orthodontics* 2000; 22: 85-92
23. Shaw A M, Sameshima G T, Vu H V. Mechanical stress generated by orthodontic forces on apical root cementum: a finite element model. *Orthodontics and Craniofacial Research* 2004;7:98-107
24. Sameshima T G, Sinclair M P. Predicting and preventing root resorption: Part I. Diagnostic factors. *American Journal of Orthodontics and Dentofacial Orthopedics* 2001; 119(5): 505-510
25. Zahrowski J, Jeske A. Apical root resorption is associated with comprehensive orthodontic treatment but not clearly dependent on prior tooth characteristics or orthodontic techniques. *Research clinical summaries* 2011; 142(1): 66-68
26. Weltman B, Vig K W L, Fields H W, Shanker S, Kaizar E E. Root resorption associated with orthodontic tooth movement: A systematic review. *American Journal of Orthodontics and Dentofacial Orthopedics* 2010; 134(4): 462-476
27. Faltin R M, Faltin K, Sander F G, Arana-Chavez V E. Ultrastructure of cementum and periodontal ligament after continuous intrusion in humans: a transmission electron microscopy study. *European Journal of Orthodontics* 2001; 3: 35-49
28. Ren Y, Maltha JC, Kuijpers-Jagtman AM. Tooth movement characteristics in relation to root resorption in young and adult rats. *European Journal of Oral Sciences* 2007; 115: 449-453



29. Montenegro V C J, Jones A, Petocz P, Gonzales C, Darendeliler M A. Physical properties of root cementum: Part 22. Root resorption after the application of light and heavy extrusive orthodontic forces: A microcomputed tomography study. *American Journal of Orthodontics* 2012; 141(1): 1-9
30. Martins D C, Tibola D, Janson G, Rogério F, Maria T. Effects of intrusion combined with anterior retraction on apical root resorption. *European Journal of Orthodontics* 2012; 34: 170-175
31. Carrillo R, Rossouw P E, Franco P F, Opperman L A, Buschang P H. Intrusion of multiradicular teeth and related root resorption with mini-screw implant anchorage: A radiographic evaluation. *American Journal of Orthodontics and Dentofacial Orthopedics* 2007; 132(5): 647-655
32. Barbagallo L J, Jones A S, Petocz P, Darendeliler M A. Physical properties of root cementum: Part 10. Comparison of the effects of invisible removable thermoplastic appliances with light and heavy orthodontic forces on premolar cementum. A microcomputed-tomography study. *American Journal of Orthodontics and Dentofacial Orthopedics* 2008; 133(2): 218-227
33. Chan E, Darendeliler M A. Physical properties of root cementum: Part 7. Extent of root resorption under areas of compression and tension. *American Journal of Orthodontics and Dentofacial Orthopedics* 2006; 129(4): 504-510
34. Ballard D J, Jones A S, Petocz P, Darendeliler M A. Physical properties of root cementum: Part 11. Continuous vs intermittent controlled orthodontic forces on root resorption. A microcomputed-tomography study. *American Journal of Orthodontics and Dentofacial Orthopedics* 2009; 136(1): 8



35. Krishnan V, Davidovitch Z. Cellular, molecular, and tissue-level reactions to orthodontic force. *American Journal of Orthodontics and Dentofacial Orthopedics* 2006; 129(4): 469
36. Weiland F. Constant versus dissipating forces in orthodontics: the effect on initial tooth movement and root resorption. *European Journal of Orthodontics* 2001; 25:335-342
37. Cuoghi O A, Aiello C A, Consolaro A, Tondelli P M, de Mendonça M R. Resorption of roots of different dimension induced by different types of forces. *Original research Orthodontics* 2014; 26(1); 1-7
38. Deguchi T, Murakami T, Kuroda S, Yabuuchi T, Kamioka H, Takano-Yamamoto T. Comparison of the intrusion effects on the maxillary incisors between implant anchorage and J-hook headgear. *American Journal of Orthodontics and Dentofacial Orthopedics*; 133(5): 654-660
39. Costopoulos G, Nanda R. An evaluation of root resorption incident to orthodontic intrusion. *American Journal of Orthodontics and Dentofacial Orthopedics* 1996; 109(5): 543-548
40. Sehr K, Bock N C, Serbesis C, Hönemann M, Ruf S. Severe external apical root resorption—local cause or genetic predisposition?. *Journal of Orofacial Orthopedics* 2011; 71: 321-331
41. Van Parys K, Aartman I, Kuitert R and Zentner A. Relationship between dental anomalies and orthodontic root resorption of upper incisors. *European Journal of Orthodontics* 2012; 34: 571-574



42. Mavragani M, Apisariyakul J, Brudvik P, Selvig K A. Is mild dental invagination a risk factor for apical root resorption in orthodontic patients?. *European Journal of Orthodontics* 2006; 28: 307-312
43. Liou E J W, Chang P M H. Apical root resorption in orthodontic patients with en-masse maxillary anterior retraction and intrusion with miniscrews. *American Journal of Orthodontics and Dentofacial Orthopedics* 2010; 137(2): 207-212
44. Brin I, Tulloch J F C, Koroluk L, Philips C. External apical root resorption in Class II malocclusion: A retrospective review of 1- versus 2-phase treatment. *American Journal of Orthodontics* 2003; 124(2): 151-156
45. Brudvik P, Rygh P. The initial phase of orthodontic root resorption incident to local compression of the periodontal ligament. *European Journal of Orthodontics* 1993; 15: 249-263
46. Lund H, Gröndahl K, Gröndahl H. Cone Beam Computed Tomography for Assessment of Root Length and Marginal Bone Level during Orthodontic Treatment. *Angle Orthodontist* 2010; 80(3): 466-473
47. Karadeniz E I, Gonzales C, Nebioglu-Dalci O, Dwarte D, Turk T, Isci D, Sahin-Saglam A M, Alkis H, Elekdag-Turk S, Darendeliler M A. Physical properties of root cementum: Part 20. Effect of fluoride on orthodontically induced root resorption with light and heavy orthodontic forces for 4 weeks: A microcomputed tomography study. *American Journal of Orthodontics* 2011; 140(5): 199-210
48. Gonzales C, Hotokezaka Karadeniz E I, Miyazaki T, Kobayashi E, Darendeliler M A, Yoshida N. Effects of fluoride intake on orthodontic tooth movement and orthodontically induced root resorption. *American Journal of Orthodontics* 2011. 139(2): 196-205



49. Aras B, Cheng L L, Turk T, Elekdag-Turk S, Jones A S, Darendeliler M A. Physical properties of root cementum: Part 23. Effects of 2 or 3 weekly reactivated continuous or intermittent orthodontic forces on root resorption and tooth movement: A microcomputed tomography study. *American Journal of Orthodontics* 2012; 141(2): 29-37
50. Liu L, Igarashi K, Haruyama N, Saeki S, Shinoda H, Mitani H. Effects of local administration of clodronate on orthodontic tooth movement and root resorption in rats. *European Journal of Orthodontics* 2004; 26:469-473
51. Loberg E L, Engström C. Thyroid administration to reduce root resorption. *The Angle Orthodontist* 1994; 64(5): 395-400
52. Poumpros E, Loberg E, Engström C. Thyroid function and root resorption. *The Angle Orthodontist* 1994; 64(5): 389-393
53. Shirazi M, Dehpour A R, Jafari F. The effect of thyroid hormone on orthodontic tooth movement in rats. *The Journal of clinical pediatric dentistry* 199; 23(3):259-264
54. Sirisoontorn I, Hotokezaka H, Hashimoto M, Gonzales C, Luppapanornlarp S, Darendeliler M A, Yoshida N. Orthodontic tooth movement and root resorption in ovariectomized rats treated by systemic administration of zoledronic acid. *American Journal of Orthodontics* 2012; 141(5): 563-573
55. El-Bialy T, El-Shamy I, Graber T M. Repair of orthodontically induced root resorption by ultrasound in humans. *American Journal of Orthodontics and Dentofacial Orthopedics* 2004; 126(2): 186-193





56. Erkan M, Pikdoken L, Usumez S. Gingival response to mandibular incisor intrusión. . American Journal of Orthodontics and Dentofacial Orthopedics 2007; 132(2): 143
57. Brin I, Tulloch J F C, Koroluk L, Philips C. External apical root resorption in Class II malocclusion: A retrospective review of 1- versus 2-phase treatment. American Journal of Orthodontics and Dentofacial Orthopedics 2003; 124(2): 151-156
58. Sameshima G T, Asgarifar K O. Assessment of Root Resorption and Root Shape: Periapical vs Panoramic Films. Angle Orthodontist 2001; 71(3): 185-189
59. Chaushu S, Kaczor-Urbanowicz K, Zadurska M, Becker A. Predisposing factors for severe incisor root resorption associated with impacted maxillary canines. American Journal of Orthodontics and Dentofacial Orthopedics 2015; 147(1): 52-60
60. Gül den N, Eggermann T, Zerres K, Beer M, Meinelt A, Diedrich P. Interleukin-1 Polymorphisms in Relation to External Apical Root Resorption (EARR). Journal of Orofacial Orthopedics 2009;70:20-38
61. Zhang D, Goetz W, Braumann B, Bourauel C, Jaeger A. Effect of soluble receptors to interleukin-1 and tumor necrosis factor alpha on experimentally induced root resorption in rats. Journal of Periodont Research 2003; 38; 324–332
62. Hartsfield JK Jr, Everett ET, Al-Qawasmi (2004) Genetic factors in external apical root resorption and orthodontic treatment. Crit Rev Oral Biol Med 15:115–122



63. Mandall N A, Lowe C, Worthington H V, Sandler J, Derwent S, Abdi-Oskouei M, S. Ward. Which orthodontic archwire sequence? A randomized clinical trial. *European Journal of Orthodontics* 2006; 28: 561-566
64. Sarikaya S, Haydar B, Ciger S, Ariyürek M. Changes in alveolar bone thickness due to retraction of anterior teeth. *American Journal of Orthodontics and Dentofacial Orthopedics* 2002; 122(1); 15-26
65. Silveira G S, de Gauw J H, Motta A T, Mucha N J. Compensatory orthodontic treatment for maxillary deficiency: A 4-year follow-up. *American Journal of Orthodontics* 2014; 146(2): 227-237
66. Chandhoke T K , Agarwal S, Feldman J, Shah R A, Upadhyay M, Nanda R. An efficient biomechanical approach for the management of an impacted maxillary central incisor. *American Journal of Orthodontics and Dentofacial Orthopedics* 2014; 146(2):249-256



