

Letters to the Editor

Primary hepatic neuroendocrine tumor in a patient with acute HBV hepatitis: An unusual neoplasia

Key words: Primary hepatic neuroendocrine tumor. Hepatitis B. Liver tumor.

Dear Editor,

We present the case of a 67-year-old woman with no previous medical history, with a flu-like clinic of 14 days, associated with arthralgia and jaundice. Additional tests showed hyperbilirubinemia (TB: 12.03 mg/dL) and liver enzymes with a hepatocellular injury pattern (AST: 1906 IU/L, ALT: 1611 IU/L). Studies were conducted, with viral markers: HBsAg: 1351; HBeAg: 12.39; HBc IgM: 27.17 and HBV DNA-426, and abdominal ultrasonographic: Solid liver lesion (SLL) in segment IV adjacent to the portal vein of 21x17 mm. With the diagnosis of acute VHB hepatitis and SLL, diagnostic tests were extended. The abdominal CT (Fig. 1) and MRI showed the lesion described between segments III and IV suggestive of hepatocellular carcinoma.

Liver biopsy (FNA) was performed giving a result of periportal and lobular chronic hepatitis, the SLL biopsy could not be performed due to its location.

After the conversion to negative of HBsAg and HBc, the anti-HBs positivity (acute hepatitis cured) and facing the suggestive HCC lesion, resection of segment IVa was performed, with intraoperative ultrasound that ruled out cirrhosis and other intrahepatic tumors. Highly favorable postoperative course, patient discharged on the fourth postoperative day. Pathology described a 3x3x2.5 cm tumor with poorly defined edges and free margins.

Histological examination showed organoid architecture and trabecular areas with cellular elements of round nuclei with clumped chromatin, and immunohistochemical techniques showed synaptophysin +, chromogranin -, and a proliferation rate of 5% compatible with a nonfunctioning primary hepatic neuroendocrine tumor (PHNT).

Given the findings, a PET-SCAN was made without observing other injuries and chromogranin A was in normal range.

Two years after surgery, the patient has had no recurrence.

Discussion

The primary location in the liver of neuroendocrine tumors is rare, because when the liver presents such tumors, the disease is usually metastatic (more than 80% are metastases) (1). The PHNT represents 0.3% of neuroendocrine tumors (2). They appear in middle-aged population (40-50 years) with no sex predilection. Usually at diagnosis, the tumors are large because

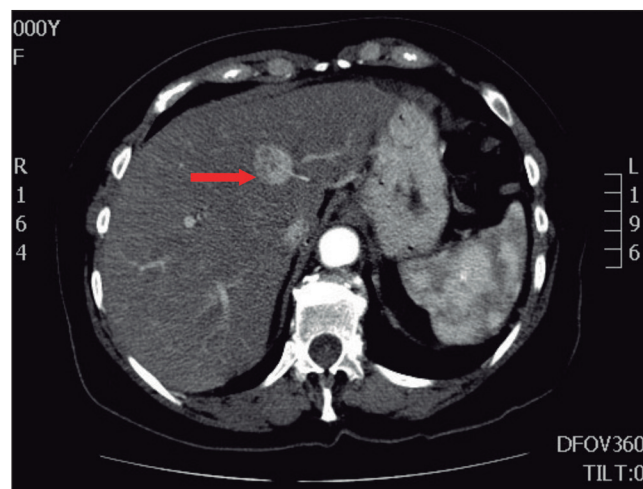


Fig. 1. Abdominal CT, arterial phase contrast hyperenhancement PHNET of 25 x 20 mm and presence of feeder vessel (arrow).

most are asymptomatic; if there are symptoms, these are strain or right upper quadrant pain, weight loss, fatigue and fever (3) and they do not usually have carcinoid syndrome (4).

Some authors have reported cases of PHNT in patients with previous liver disease (hepatitis B or cirrhosis), but an association between the two has not been demonstrated (5,6).

The differential diagnosis is made with hepatocellular carcinoma and intrahepatic cholangiocarcinoma, showing negativity for markers such as AFP, CEA and CA 19-9 (3). Blood serotonin, chromogranin A, or 5-hydroxyindoleacetic acid in urine may be high (6). The imaging tests most commonly used are ultrasound, CT and MRI. The octreoscan and PET-CT with 18F-FDG can detect tumors up to 2 mm and occult foci (6). The final diagnosis needs histological confirmation with generally positive immunohistochemistry for chromogranin A, neuro-specific enolase, and synaptophysin (7,8) and requires to fulfill another premise: exclude extrahepatic localization, since in that case it would then be a metastasis (3,5,9).

Surgery with complete resection is the accepted treatment for PHNT, with recurrences of 18% and survival at 5 years of 74-78% (3,9,10).

Germán Mínguez-Ruiz¹, Carmen García-Bernardo¹,
Jimi Harold Jara-Quezada¹, Raquel Rodríguez-Uría¹,
M.^a Luisa González-Diéguez¹ and Lino Vázquez-Velasco¹

*Departments of ¹General Surgery and ²Digestive Diseases.
Hospital Universitario Central de Asturias. Oviedo, Spain*

References

1. Modlin IM, Sandor A. An analysis of 8305 cases of carcinoid tumors. *Cancer* 1997;79:813-29.
2. Fenoglio LM, Severini S, Ferrigno D, et al. Primary hepatic carcinoid: A case report and literature review. *World J Gastroenterol* 2009; 15:2418-22.
3. Zhu H, Sun K, Ward SC, et al. Primary hepatic signet ring cell neuroendocrine tumor: A case report with literature review. *Semin Liver Dis* 2010;30:422-8.
4. Modlin IM, Kidd M, Latich I, et al. Current status of gastrointestinal carcinoids. *Gastroenterology* 2005;128:1717-51.
5. Jia C, Zhang Y, Xu J, et al. Experience in primary hepatic neuroendocrine tumor. *Turk J Gastroenterol* 2012;23:546-51.
6. Huang YQ, Xu F, Yang JM, et al. Primary hepatic neuroendocrine carcinoma: Clinical analysis of 11 cases. *Hepatobiliary Pancreat Dis Int* 2010;9:44-8.
7. Dala R, Shoosmith J, Lilenbaum R, et al. Primary hepatic neuroendocrine carcinoma: An underdiagnosed entity. *Ann Diagn Pathol* 2006;10:28-31.
8. Erickson LA, Lloyd RV. Practical markers used in the diagnosis of endocrine tumors. *Adv Anat Pathol* 2004;11:175-89.
9. Knox CD, Anderson CD, Lamps LW, et al. Long-term survival after resection for primary hepatic carcinoid tumor. *Ann Surg Oncol* 2003;10:1171-5.
10. Woodside KJ, Townsend CM, Evers BM. Current management of gastrointestinal carcinoid tumors. *J Gastrointest Surg* 2004;8:742-56.