



ELSEVIER

Contents lists available at ScienceDirect

JPRAS Open

journal homepage: <http://www.journals.elsevier.com/jpras-open>

## Original Article

# Connections between the facial and trigeminal nerves: Anatomical basis for facial muscle proprioception

J.L. Cobo <sup>a, b, f</sup>, A. Solé-Magdalena <sup>a, f</sup>, I. Menéndez <sup>c, d</sup>, J.C. de Vicente <sup>b, c</sup>,  
J.A. Vega <sup>a, e, \*</sup>

<sup>a</sup> Departamento de Morfología y Biología Celular, Grupo SINPOS, Sección de Anatomía y Embriología Humana, Universidad de Oviedo, Oviedo, Spain

<sup>b</sup> Servicio de Cirugía Maxilofacial, Hospital Universitario Central de Asturias, Oviedo, Spain

<sup>c</sup> Departamento de Cirugía y Especialidades Médico-Quirúrgicas, Área de Odontología, Universidad de Oviedo, Oviedo, Spain

<sup>d</sup> Instituto Asturiano de Odontología (IAO), Oviedo, Spain

<sup>e</sup> Facultad de Ciencias de la Salud, Universidad Autónoma de Chile, Santiago de Chile, Chile

## ARTICLE INFO

## Article history:

Received 19 January 2017

Accepted 22 January 2017

Available online 9 February 2017

## Keywords:

Proprioception

Proprioceptors

Facial muscles

Trigeminal-facial nerve connections

## ABSTRACT

Proprioception is a quality of sensibility that originates in specialized sensory organs (proprioceptors) that inform the central nervous system about static and dynamic conditions of muscles and joints. The facial muscles are innervated by efferent motor nerve fibers and typically lack proprioceptors. However, facial proprioception plays a key role in the regulation and coordination of the facial musculature and diverse reflexes. Thus, facial muscles must be necessarily supplied also for afferent sensory nerve fibers provided by other cranial nerves, especially the trigeminal nerve. Importantly, neuroanatomical studies have demonstrated that facial proprioceptive impulses are conveyed through branches of the trigeminal nerve to the central nervous system. The multiple communications between the facial and the trigeminal nerves are at the basis of these functional characteristics. Here we review the literature regarding the facial (superficial) communications between the facial and the trigeminal nerves, update the current knowledge about proprioception in the facial muscles, and hypothesize future research in facial proprioception.

© 2017 The Author(s). Published by Elsevier Ltd on behalf of British Association of Plastic, Reconstructive and Aesthetic Surgeons. This is an open access article under the CC BY-NC-ND license (<http://creativecommons.org/licenses/by-nc-nd/4.0/>).

\*Corresponding author. Departamento de Morfología y Biología Celular, Facultad de Medicina y Ciencias de la Salud – Universidad de Oviedo, C/Julián Clavería, 6 – Planta 9ª, 33006 Oviedo, Spain. Fax: +34 985103618.

E-mail address: [javega@uniovi.es](mailto:javega@uniovi.es) (J.A. Vega).

<sup>f</sup> Both authors contributed equally to this paper.

## Introduction

Proprioception is the quality of mechanosensibility that informs the central nervous system about the static and dynamic conditions of muscles and joints.<sup>1,2</sup> It originates in specialized sensory organs (proprioceptors) that include muscle spindles and Golgi's tendon organs.<sup>3–5</sup> Furthermore, capsular joint mechanoreceptors and certain kinds of cutaneous mechanoreceptors can also work as proprioceptors.<sup>6–9</sup> Proprioception applies for all skeletal muscles, including the craniocephalic ones. However, although muscles innervated by the trigeminal nerve (cranial nerve V: CNV) contain proprioceptors,<sup>10,11</sup> those innervated by the facial (cranial nerve VII: CNVII) or the glossopharyngeal nerves<sup>12,13</sup> lack typical proprioceptors. However, facial proprioception plays a key role in facial expression, the coordination of facial movement,<sup>14,15</sup> regulation of the masticatory force in conjunction with jaw muscles, oromotor behaviors, and nonverbal facial communication and in orofacial reflexes related to speech, swallowing, cough, vomiting, or breathing.<sup>16–19</sup>

Some decades ago, Baumel<sup>20</sup> suggested that proprioceptive impulses from facial muscles are conveyed through the branches of CNV, which innervate the skin of the facial muscles regulating facial expression and establish multiple communications with the branches of CNVII. Presently, it is widely accepted that the proprioception of all the craniocephalic muscles depends on CNV,<sup>13,22</sup> and the connections between CNV and CNVII may explain, at least in part, why trigeminal afferents transmit proprioceptive information from the face to the mesencephalic trigeminal nucleus for processing.<sup>13</sup>

Moreover, and despite the facial muscles lacking typical proprioceptors, proprioceptive acuity of the orofacial muscles has been found to be more accurate than that of the jaw.<sup>21</sup> All together, these data suggest complex interaction between CNV and CNVII, which is of capital importance to understand the clinical features of these nerves and in the surgery involving them to preserve proprioception in face transplantation as much as possible,<sup>22,23</sup> in reconstructive and cosmetic facial plastic surgery,<sup>24</sup> or in minimally invasive procedures (i.e., botulinum toxin; Refs. 25–28).

Here we review the literature and add our own experience devoted to the facial (superficial) communications between CNVII and CNV. In addition, we updated the current knowledge about proprioception in the facial muscles, which provide an anatomical support in these communications.

## An overview of the trigeminal and facial nerves

CNV and CNVII are both mixed cranial nerves that carry motor and sensory fibers responsible for both the motor and sensory innervation of the face, respectively. Moreover, with several deep and superficial connections, CNV is considered responsible for the proprioceptive innervation of the head muscles. Moreover, CNVII and some branches of CNV contain pre- and postganglionic parasympathetic nerve fibers.<sup>29–31</sup>

CNV is responsible for the sensory innervation of the face and the motor innervation of several craniocephalic muscles (*temporalis*, *masseter*, *pterygoideus medialis* and *lateralis*, *mylohyoideus*, *venter anterior digastricus*, *tensor veli palatine*, and *tensor tympani*). It originates with two roots at the mid-lateral surface of the pons that reach the Gasser's ganglion (*ganglion trigeminale*) where it divides into three branches: ophthalmic (*n. ophthalmicus*, sensory V1), maxillary (*n. maxillaris*, sensory V2), and mandibular (*n. mandibularis*, mixed V3). The soma of the sensory neurons is localized in the *ganglion trigeminale* and terminates in the brainstem trigeminal sensory nuclei (*nucleus spinalis nervi trigeminalis* and *nucleus principalis nervi trigemini*). However, the proprioceptive neurons that innervate the craniofacial muscles innervated by V3 are located in the *nucleus mesencephalicus nervi trigemini* instead of the *ganglion trigeminale*. The motor axons originate from neurons located in the masticator nucleus (*nucleus motorius nervi trigemini*) and are integrated into the mandibular nerve. From a developmental perspective, the ophthalmic branch innervates the derivatives of the frontonasal process of the embryos, and the maxillary and mandibular branches innervate the derivatives maxillary and mandibular processes of the first branchial arch.

CNVII is responsible for the innervation and control of the movements of all the craniofacial muscles, with the exception of the jaw muscles. Moreover, it innervates the *platysma*, *venter anterior*

*digastricus*, *stylohyoideus*, and *stapedius* muscles. The sensory portion of CNVII receives gustatory perception from the anterior two-thirds of the tongue and from a small cutaneous segment related to the outer ear, the so-called Ransey-Hunt's zone. CNVII originates with two roots at the pontomedullary sulcus of the brainstem near the pontocerebellar angle, with the largest being the motor root and the smaller being the sensory root (the so-called intermediate Wrisberg's nerve; *n. intermedius*). Thereafter, it enters the temporal bone, continues through the facial canal (where the two roots fuse), and emerges from the *foramen stylomastoideum*. Then, it passes through the parotid gland, bifurcates into two trunks (temporofacial and cervicofacial), and divides into five major branches (with wide variations): temporal (*r. temporales*), the zygomatic (*r. zygomatici*), the buccal (*r. buccales*), mandibular (*r. marginalis mandibularis*), and the cervical (*r. cervicales*).<sup>32,33</sup> In addition, in some cases, an aberrant branch emerges that arises from the main trunk before bifurcation into the temporofacial and cervicofacial divisions.<sup>34</sup> However, numerous anatomical variants and connections between the facial nerve branches have been described in both children and adults.<sup>35,36</sup> The soma of the sensory neurons is localized in the *ganglion geniculatum* and terminates centrally in the brainstem *nucleus tractus solitarius*. The motor axons originate from neurons located in the brainstem *nucleus nervi facialis*. From a developmental perspective, the facial nerve innervates the derivatives of the second branchial arch of the embryos.

### Innervation of the facial muscles

To understand the proprioceptive innervation of the facial muscles, it is necessary to know that as they are consistently innervated by the CNVII branches, the "enrichment" of the terminal segments of the facial nerves with sensory fibers from CNV might provide these muscles with proprioceptive fibers.

All the craniofacial muscles, except the jaw ones are innervated by CNVII. According to Marur et al.,<sup>37</sup> the innervation of the facial muscles is as follows: the temporal branch innervates the *frontalis*, *procerus*, *depressor supercillii*, and *corrugator supercillii* muscles; the temporal and zygomatic branches supply the *orbicularis oculi* muscle; the zygomatic and buccal branches innervate the *zygomaticus major*, *zygomaticus minor*, *levator labii superioris aequae nasi*, and *levator anguli oris*; the buccal branches exclusively innervate the *buccinator* and *risorius* muscles; the marginal mandibular and buccal branches innervate the *orbicularis oris* muscle; the marginal mandibular branch of the facial nerve supplies the *depressor anguli oris*, *depressor labii inferioris*, and *mentalis* muscles; and the cervical branch of the facial nerve innervates the *platysma*.

It can therefore be assumed that communications between specific CNV and CNVII branches provide proprioceptive innervation to concrete muscles (Table 1), although individual differences may exist, and some muscles can receive innervation from more than a trigeminal branches.

### Superficial branches of the trigeminal and facial nerves

In the present review, only the superficial branches of CNV and CNVII innervating the face will be considered, especially the cutaneous branches arising from CNV because all the branches of the facial nerve should be regarded as superficial.

The branches of CNV that have a subcutaneous trajectory are (i) from the ophthalmic division: the supraorbital (*n. supraorbitalis*) and supratrochlear (*n. supratrochlearis*) nerves (originated from the division of the frontal nerve), the upper eyelid branches of the lachrymal nerve (*n. lacrimalis*), the external nasal branch (*r. nasales laterales*) of the anterior ethmoidal nerve (*n. ethmoidalis anterior*; originated from the nasociliary nerve), and the infratrochlear nerve (*n. infratrochlearis*); (ii) from the maxillary division: the infraorbital nerve (*n. infraorbitalis*), which emerges onto the face from the infraorbital foramen, and the zygomaticofacial nerve (*r. zygomaticotemporalis*); (iii) from the mandibular division: the auriculotemporal nerve (*n. auriculotemporalis*), the buccal nerve (*n. buccalis*), and the inferior alveolar (*n. alveolaris inferior*) and mental (*n. mentalis*) nerves. It is generally agreed upon that CNVII runs deep to the facial superficial musculoaponeurotic system (SAMS), and only sensory nerves (CNV) pass through the SMAS to provide innervation to the facial skin, but this topographical division is not universally accepted.<sup>38–40</sup>

**Table 1**

Several trigeminal nerve branches (left column) communicate with the main divisions of the facial nerve (central column) to provide sensory innervation to the muscles (right column) they innervate. Therefore, the facial muscles innervated by a branch of the facial nerve also receive fibers from the trigeminal branch with which it communicates, and each facial muscle receives both motor (facial) and sensory (trigeminal) innervation. Data in this table are based on the literature cited in the manuscript.

Trigeminal connections with	Facial nerve branches	Facial muscles innervated
Auriculotemporal	Facial trunk	
Great auricular nerve	Temporofacial and cervicofacial divisions	
Zygomaticotemporal	Temporal	Frontalis
Supraorbital		Procerus
Auriculotemporal		Depressor supercilii
		corrugator supercilii
		Orbicularis oculi
Supraorbital	Zygomatic	Orbicularis oculi
Supratroclear		Zygomaticus major
Buccinators		Zygomaticus minor
Buccal		Levator labii superioris aleque nasi
Zygomaticofacial		Levator anguli oris
Auriculotemporal		
Infratrochlear	Buccal	Orbicularis oculi Zygomaticus major
Infraorbital		Zygomaticus minor
Buccal		Levator labii superioris aleque nasi
(communicating buccal nerve)		Levator anguli oris
Mental		Buccinators
Buccinator zygomaticofacial		Risorius
Auriculotemporal		
Buccinator	Marginal mandibular	Orbicularis oris
Mental		Depressor anguli oris depressor labii inferioris mentalis
	Cervical	Platysma

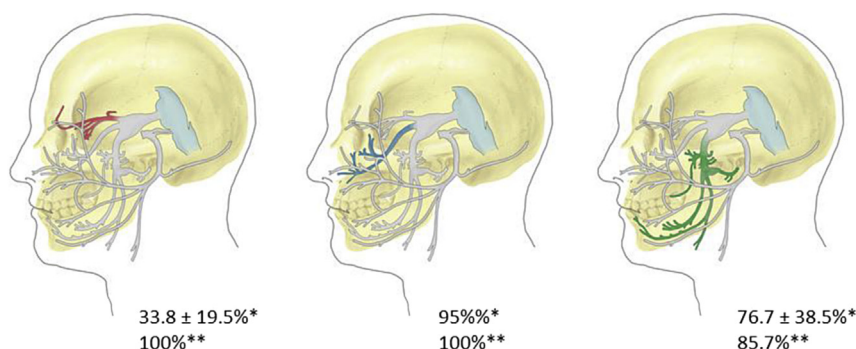
## Facial and trigeminal nerve communications

CNVII exhibits a highly variable and complicated branching pattern and forms communications with several other cranial nerves, especially with the branches of all the three divisions of CNV.<sup>41–44</sup> A review of the available studies on trigeminofacial communications by Hwang et al<sup>45</sup> shows that in studies using dissection, the maxillary branch had the highest frequency ( $95.0\% \pm 8.0\%$ ) of communication with CNVII, followed by the mandibular branch ( $76.7\% \pm 38.5\%$ ) and the ophthalmic branch ( $33.8\% \pm 19.5\%$ ). However, when the Sihler's stain method was used to stain the nerves, it was observed that all the maxillary and mandibular branches, and 85.7% (12/14 hemi-faces) of the ophthalmic branches had communications with the facial.<sup>46</sup> Interestingly, communication between the infraorbital nerve and the different branches of CNVII are regularly found just below the infraorbital foramen, forming the infraorbital plexus<sup>47–49</sup> (Figure 1).

CNVII can receive proprioceptive information from the cervical nerves, which are frequency communicated ( $65.2 \pm 43.5\%$ ; Ref. 45).

### Communications of trunk and two major divisions of the facial nerve with the trigeminal nerve

The auriculotemporal nerve shows unique multiple communications with the CNVII trunk, which are known as communicating auriculotemporal nerves, and are highly consistent yet highly variable in their communication patterns.<sup>48,50,51</sup> The observations of Kwak et al<sup>48</sup> of over 30 hemi-heads showed that these communications occur within the parotid gland (93.3% of the cases) and join the upper division (temporofacial) of the facial nerve posteriorly at the border of the masseter. Functionally, these communications consistently innervate some of the muscles responsible for upper facial expression (e.g., frontalis, orbicularis oculi, and zygomaticus major muscles)<sup>50</sup> and presumably are also responsible for their proprioception.



**Figure 1.** Schematic representation of the three trigeminal nerve branches, namely ophthalmic (red), maxillary (blue), and mandibular (green), and their relationships with the facial nerve. Numbers indicate the percent of communications between the three main trigeminal branches and the facial nerve (without specification of the branch) in cadaveric dissections (\*; Ref. 45) or using the Sihler stain method (\*\*; Ref. 46). The image was modified from the original by Diamond et al.<sup>43</sup>

Interestingly, although independent of CNV, a connection between the great auricular nerve (composed of branches of spinal nerves C2 and C3) and CNVII trunk has been consistently observed (100%) in 25 adult cadavers.<sup>52</sup>

#### *Communications of the temporal branch of the facial nerve with the trigeminal nerve (Figure 2A)*

Shimada et al,<sup>51</sup> and more recently Odobescu et al,<sup>53</sup> described the connections between the zygomaticotemporal nerve of CNV2 and temporal branches of CNVII piercing the superficial layer of the deep temporal fascia. Moreover, the temporal branch receives connection from the horizontal branch of the supraorbital nerve<sup>42</sup> [44% according to Hwang et al<sup>54</sup>; 85.7% according to Yang et al<sup>46</sup>] and the auriculotemporal nerve.<sup>42</sup>

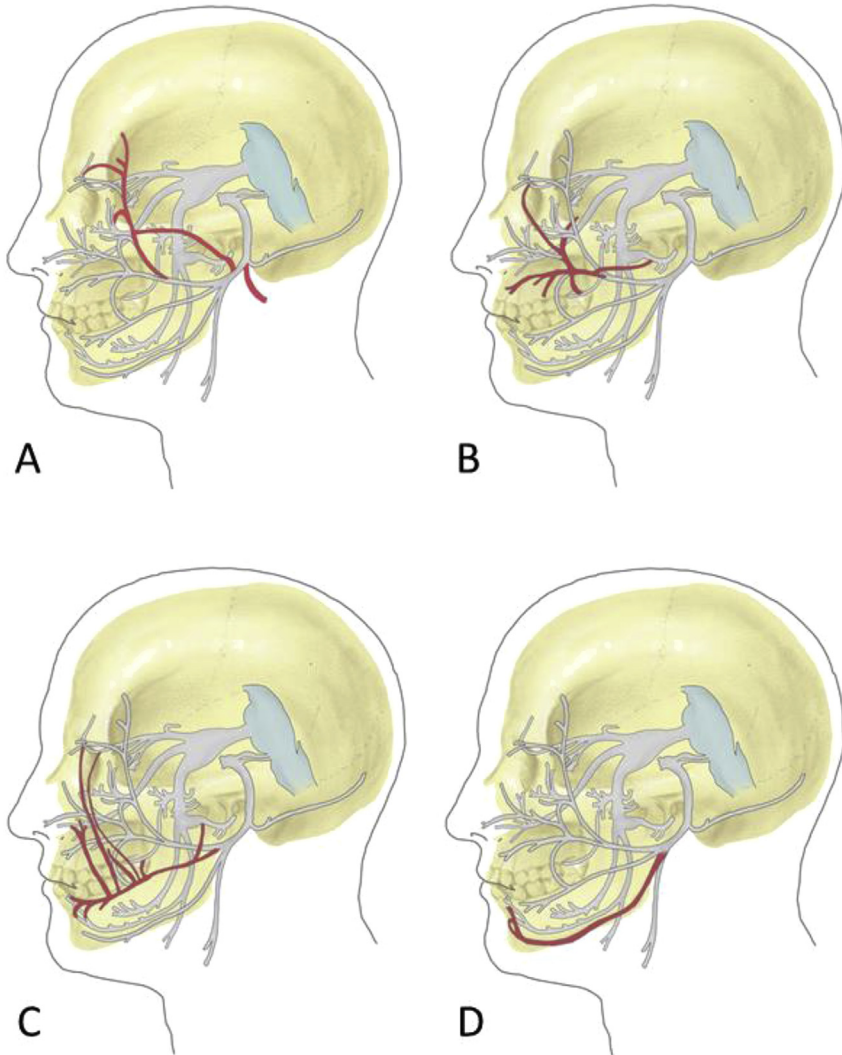
#### *Communications of the zygomatic branch of the facial nerve with the trigeminal nerve (Figure 2B)*

The zygomatic branch of CNVII is anastomosed with the buccal nerve of CNV3<sup>55</sup> and the zygomaticofacial nerve of CNV2.<sup>51</sup> This connection may be related with both the interchange of sensory fibers and postganglionic parasympathetic secretomotor directed to the lacrimal gland.<sup>56</sup> Furthermore, connections between the zygomatic branch and the auriculotemporal, supraorbital, buccinator,<sup>42</sup> and supratrochlear (50%)<sup>46</sup> nerves were demonstrated.

#### *Communications of the buccal branch of the facial nerve with the trigeminal nerve (Figure 2C; Figures 3 and 4)*

The buccal nerve, a sensory branch of CNV3, communicates with the buccal branch of CNVII at its peripheral position through a thick branch commonly called the communicating buccal nerve,<sup>51,55,57</sup> which is located at the outer layer of deep fascia of the anterior portion of the *buccinator* muscle<sup>55</sup> or within the *buccinator* and *orbicularis oris* muscles.<sup>51</sup> Moreover, the buccal branch communicates with the infraorbital, buccinators, and auriculotemporal nerves<sup>46</sup>; the infratrochlear, infraorbital, and zygomaticofacial nerves [85.7%, 28.6% and 41.7% of the cases, respectively<sup>46</sup>]; and the mental nerve.<sup>51,58</sup>

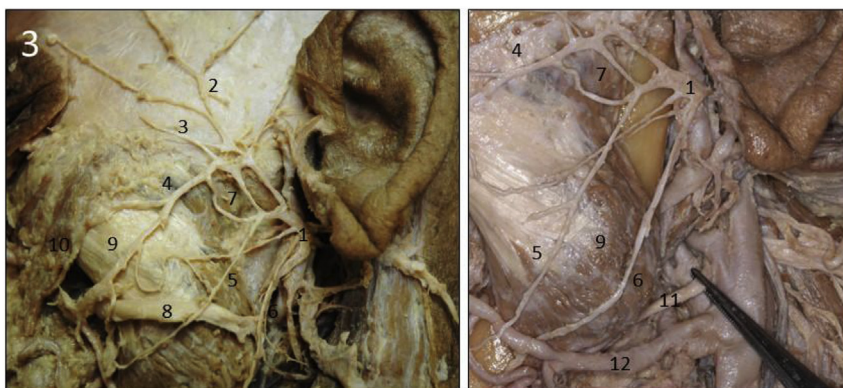A recent cadaveric study conducted on 40 hemi-faces by Tansatit et al<sup>59</sup> identified triple (25%), double (62.5%), and single (10%) communications between the buccal branch of the facial nerve and the infraorbital nerve of the trigeminal nerve. The most common type of communication occurred between the lower trunk of the buccal nerve and the lateral labial branch of the infraorbital nerve (70%) deep to the *levator labii superioris* muscle. In Yang's et al's<sup>46</sup> study, the communications between these nerves reached 100%.



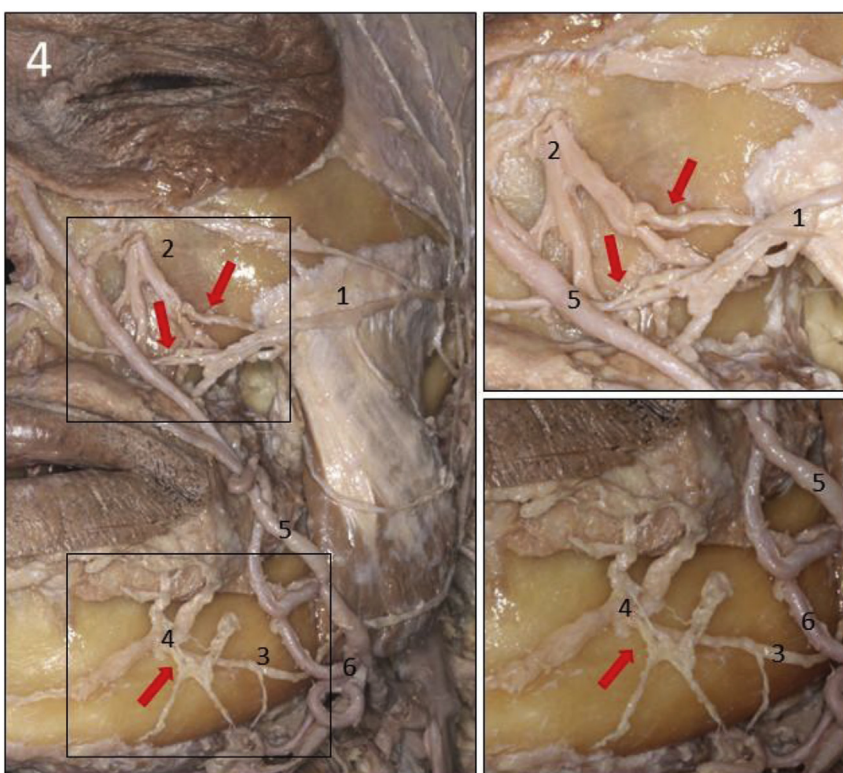
**Figure 2.** Schematic representation of the communications between the four main branches of the facial nerve, namely temporal (A), zygomatic (B), buccal (C), and marginal mandibular (D), with the superficial trigeminal branches. These nerves and the connections with the trigeminal branches are colored in red. The image was modified from the original by Diamond et al.<sup>43</sup>

*Communications of the mandibular branch of the facial nerve with the trigeminal nerve (Figure 2D; Figures 3 and 4)*

Several authors have reported interconnections between the marginal mandibular branch of CNVII and the mental nerve of CNV3 in 100% of the cases.<sup>41,46,51,58,60</sup> Moreover, the marginal mandibular nerve is anastomosed with the buccinator nerve.<sup>46</sup> The frequency of communication between the cervical branch and the marginal mandibular branch of the facial nerve was  $24.7 \pm 1.7\%$ .<sup>45</sup>



**Figure 3.** Cadaveric dissection of the left facial nerve in a male, 66 years old. The parotid gland, but not the parotid duct, was removed. The facial nerve branched within the parotid gland into five branches, which were largely connected at the initial segments. 1: facial nerve, 2: temporal branches, 3: zygomatic branches, 4: buccal branches, 5: mandibular branches, 6: cervical branches, 7: connections between primary facial divisions, 8: parotid duct, 9: masseter muscle, 10: zygomatic major muscle, 11: facial artery, and 12: facial vein. This picture was obtained from our own dissections and was performed at the Area of Anatomy and Human Embryology, Department of Morphology and Cell Biology, University of Oviedo, Spain.



**Figure 4.** Details of the dissection of the facial nerve on the left side of a hemi-head (male, 66 years old) showing the connections observed between the infraorbital CNV2 and the zygomatic branch of CNVII (red arrow) and between the mental CNV3 and the mandibular CNVII (red arrow). 1: zygomatic branch, 2: infraorbital nerve CNV2, 3: mandibular branch, 4: mental nerve CNV3, 5: facial vein, 6: facial artery. This picture was obtained from our own dissections and was performed at the Area of Anatomy and Human Embryology, Department of Morphology and Cell Biology, University of Oviedo, Spain.

## The enigma of the facial muscles proprioception

Although the neuroanatomy and the neurology of the facial muscles is actually well known,<sup>11</sup> some aspects of their neurobiology remain elusive, and proprioception is one such aspect.<sup>11,20,61</sup> What is the manner in which the proprioceptive stimuli that originated in facial muscles reaches the central nervous system? At present, it is accepted that they are generated in CNV nerve fibers and reach the mesencephalic nucleus of CNV to be processed.<sup>11,20</sup> This necessarily implies that the trigeminal sensory nerve fibers receive proprioceptive inputs from the facial muscles, and surely, they travel along the communications between CNV and CNVII.<sup>18,19,62</sup> Therefore, accurate knowledge of these communications is necessary to preserve these communications when performing a surgical or medical intervention on the face as a disruption of these connections might alter facial muscle proprioception. These communications have clinical significance for the recovery of damaged facial expression muscles, treatment of hemi-facial spasm, and surgical procedures for facial reconstruction and neck dissection.<sup>63</sup> Surgeons and esthetic doctors should be aware of these nerve communications, which are important during facial reconstructive surgery, nerve transfer procedures, and minimally invasive surgeries. Unfortunately, there are large individual and intra-individual (left vs. right sides of the face), differences that make the identification of these nerve communications difficult; however, at least those communications that are regarded as constant must be kept in mind when acting on the face. The improvement of imaging methods<sup>64,65</sup> will probably allow to localize these communications in a few years.

Nevertheless, the facial muscles are devoid of proprioceptors, and therefore, facial movements lack a conventional proprioceptive feedback system, which is only in part vicariate by cutaneous afferents.<sup>11</sup> According to Connor and Abbs,<sup>61</sup> the sensory apparatus of the facial skin can serve the purposes of proprioception because modifications of the facial skin during facial movements result in cutaneous mechanoreceptor discharge. Mechanical forces cause the movement of skin and facial hair, which in turn activate the trigeminal ganglion mechanosensitive neuronal fibers (low-threshold mechanoreceptors) that activate the skin or hair follicles.<sup>66</sup> However, because facial muscles lack typical proprioceptors<sup>11</sup> and the cutaneous facial mechanoreceptors are unable to substitute them successfully,<sup>8,11,67</sup> further research must be conducted to identify them. Surely, new knowledge of the molecular events during the mechanotransduction<sup>68–70</sup> might contribute to solve this important biological and clinical problem.

## Conflict of interest statement

None.

## References

1. Dijkerman HC, de Haan EH. Somatosensory processes subserving perception and action. *Behav Brain Sci.* 2007;30:189–201.
2. Butler AA, Héroux ME, Gandevia SC. Body ownership and a new proprioceptive role for muscle spindles. *Acta Physiol (Oxf)*. 2016. <http://dx.doi.org/10.1111/apha.12792>.
3. Banks RW. The innervation of the muscle spindle: a personal history. *J Anat.* 2015;227:115–135.
4. Bewick GS, Banks RW. Mechanotransduction in the muscle spindle. *Pflugers Arch.* 2015;467:175–190.
5. Proske U. The role of muscle proprioceptors in human limb position sense: a hypothesis. *J Anat.* 2015;227:178–183.
6. Collins DF, Refshauge KM, Todd G, Gandevia SC. Cutaneous receptors contribute to kinesthesia at the index finger, elbow, and knee. *J Neurophysiol.* 2005;94:1699–1706.
7. Macefield VG. Physiological characteristics of low-threshold mechanoreceptors in joints, muscle and skin in human subjects. *Clin Exp Pharmacol Physiol.* 2005;32:135–144.
8. Proske U, Gandevia SC. The proprioceptive senses: their roles in signaling body shape, body position and movement, and muscle force. *Physiol Rev.* 2012;92:1651–1697.
9. Prochazka A, Ellaway P. Sensory systems in the control of movement. *Compr Physiol.* 2012;2:2615–2627.
10. Osterlund C, Liu JX, Thornell LE, Eriksson PO. Muscle spindle composition and distribution in human young masseter and biceps brachii muscles reveal early growth and maturation. *Anat Rec (Hoboken)*. 2011;294:683–693.
11. Saverino D, De Santanna A, Simone R, Cervioni S, Cattrysse E, Testa M. Observational study on the occurrence of muscle spindles in human digastric and mylohyoideus muscles. *Biomed Res Int.* 2014;2014, 294263.
12. de Carlos F, Cobo J, Macías E, et al. The sensory innervation of the human pharynx: searching for mechanoreceptors. *Anat Rec (Hoboken)*. 2013;296:1735–1746.
13. Cattaneo L, Pavesi G. The facial motor system. *Neurosci Biobehav Rev.* 2014;38:135–159.



14. van der Bilt A. Assessment of mastication with implications for oral rehabilitation: a review. *J Oral Rehabil.* 2011;38:754–780.
15. Schötz S, Frid J, Löfqvist A. Development of speech motor control: lip movement variability. *J Acoust Soc Am.* 2013;133:4210–4217.
16. Miller AJ. Oral and pharyngeal reflexes in the mammalian nervous system: their diverse range in complexity and the pivotal role of the tongue. *Crit Rev Oral Biol Med.* 2002;13:409–425.
17. Hontanilla B, Marre D. Retrospective study of the functional recovery of men compared with that of women with long-term facial paralysis. *Br J Oral Maxillofac Surg.* 2013;51:684–688.
18. Kang YS, Bae YC, Hwang SM, Nam SB. A simple and quantitative method for three-dimensional measurement of normal smiles. *Ann Plast Surg.* 2005;54:379–383.
19. Wild B, Erb M, Eyb M, Bartels M, Grodd W. Why are smiles contagious? An fMRI study of the interaction between perception of facial affect and facial movements. *Psychiatry Res.* 2003;123:17–36.
20. Baumel J. Trigeminal-facial nerve communications. *Arch Otolaryngol.* 1974;99:34–44.
21. Frayne E, Coulson S, Adams R, Croxson G, Waddington G. Proprioceptive ability at the lips and jaw measured using the same psychophysical discrimination task. *Exp Brain Res.* 2016;234:1679–1687.
22. Lazarov NE. Neurobiology of orofacial proprioception. *Brain Res Rev.* 2007;56:362–383.
23. Russo JE, Genden EM. Facial transplantation. *Facial Plast Surg Clin North Am.* 2016;24:367–377.
24. Hassouneh B, Brenner MJ. Systematic review and meta-analysis in facial plastic surgery. *Facial Plast Surg Clin North Am.* 2015;23:273–283.
25. Jia Z, Lu H, Yang X, et al. Adverse events of botulinum toxin type A in facial rejuvenation: a systematic review and meta-analysis. *Aesthetic Plast Surg.* 2016;40:769–777.
26. Commander SJ, Chang D, Fakhro A, Nigro MG, Lee EI. Noninvasive facial rejuvenation. Part 1: patient-directed. *Semin Plast Surg.* 2016;30:129–133.
27. Dickey RM, Louis MR, Cox JA, Mohan K, Lee EI, Nigro MG. Noninvasive facial rejuvenation. Part 2: physician-directed-neuromodulators and fillers. *Semin Plast Surg.* 2016;30:134–142.
28. Meaie JD, Agrawal N, Chang D, Lee EI, Nigro MG. Noninvasive facial rejuvenation. Part 3: physician-directed-lasers, chemical peels, and other noninvasive modalities. *Semin Plast Surg.* 2016;30:143–150.
29. Monhouse S. *Cranial Nerves. Functional Anatomy.* Cambridge: Cambridge University Press; 2005.
30. Wilson-Pawels L, Stewart T, Akesson EJ, Spacey SD. *Cranial Nerves. Function and Dysfunction.* 3rd ed. People's Medical Publishing House-USA; 2013.
31. Joo W, Yoshioka F, Funaki T, Mizokami K, Rhoton Jr AL. Microsurgical anatomy of the trigeminal nerve. *Clin Anat.* 2014;27:61–88.
32. Moore KL, Dalley AF. *Clinically Oriented Anatomy.* 4th ed. Baltimore: Lippincott Williams & Wilkins; 1999:859–861.
33. Vacher C, Cyna-Gorse F. Motor nerves of the face. Surgical and radiologic anatomy of facial paralysis and their surgical repair. *Ann Chir Plast Esthet.* 2015;60:363–369.
34. Wildan T, Nasser N. Aberrant temporal branch of facial nerve. *Br J Oral Maxillofac Surg.* 2016;54:e61–e63.
35. Ekinci N. A study on the branching pattern of the facial nerve of children. *Kaib Zasshi.* 1999;74:447–450.
36. Gataa IS, Faris BJ. Patterns and surgical significance of facial nerve branching within the parotid gland in 43 cases. *Oral Maxillofac Surg.* 2016;20:161–165.
37. Marur T, Tuna Y, Demirci S. Facial anatomy. *Clin Dermatol.* 2014;32:14–23.
38. Ghassemi A, Prescher A, Riediger D, Axer H. Anatomy of the SMAS revisited. *Aesthetic Plast Surg.* 2003;27:258–264.
39. Nowinski WL, Chua BC, Johnson A, et al. Three-dimensional interactive and stereotactic atlas of head muscles and glands correlated with cranial nerves and surface and sectional neuroanatomy. *J Neurosci Methods.* 2013;125:12–18.
40. Pessa JE. SMAS fusion zones determine the subfacial and subcutaneous anatomy of the human face: fascial spaces, fat compartments, and models of facial aging. *Aesthet Surg J.* 2016;36:515–526.
41. May M. Anatomy for the clinician. In: May M, Schaitkin BM, eds. *The Facial Nerve.* 2nd ed. New York: Thieme Medical Publishers; 2000.
42. Li C, Jiang XZ, Zhao YF. Connection of trigeminal nerve and facial nerve branches and its clinical significance. *Shanghai Kou Qiang Yi Xue.* 2009;18:545–550 [Article in Chinese].
43. Diamond M, Wartmann CT, Tubbs RS, Shoja MM, Cohen-Gadol AA, Loukas M. Peripheral facial nerve communications and their clinical implications. *Clin Anat.* 2011;24:10–18.
44. Shoja MM, Oyesiku NM, Griessenauer CJ, et al. Anastomoses between lower cranial and upper cervical nerves: a comprehensive review with potential significance during skull base and neck operations, part I: trigeminal, facial, and vestibulocochlear nerves. *Clin Anat.* 2014;27:118–130.
45. Hwang K, Yang SC, Song JS. Communications between the trigeminal nerve and the facial nerve in the face: a systematic review. *J Craniofac Surg.* 2015;26:1643–1646.
46. Yang HM, Won SY, Kim HJ, Hu KS. Sihler staining study of anastomosis between the facial and trigeminal nerves in the ocular area and its clinical implications. *Muscle & Nerve.* 2013;48:545–550.
47. Hwang K, Han JY, Battuvshin D, Kim DJ, Chung IH. Communication of infraorbital nerve and facial nerve: anatomic and histologic study. *J Craniofac Surg.* 2004;15:88–91.
48. Kwak HH, Park HD, Youn KH, et al. Branching patterns of the facial nerve and its communication with the auriculotemporal nerve. *Surg Radiol Anat.* 2004;6:494–500.
49. Hu KS, Kwak J, Koh KS, Abe S, Fontaine C, Kim HJ. Topographic distribution area of the infraorbital nerve. *Surg Radiol Anat.* 2007;29:383–388.
50. Namking M, Boonruangsri P, Woraputtaporn W, Gøuldner FH. Communication between the facial and auriculotemporal nerves. *J Anat.* 1994;185:421–426.
51. Shimada K, Moriyama H, Ikeda M, Tomita H, Shigihara S, Gasser RF. Peripheral communication of the facial nerve at the angle of the mouth. *Eur Arch Otorhinolaryngol.* 1994;S110–S112.
52. Yang HM, Kim HJ, Hu KS. Anatomic and histological study of great auricular nerve and its clinical implication. *J Plast Reconstr Aesthet Surg.* 2015;68:230–236.

53. Odobescu A, Williams HB, Gilardino MS. Description of a communication between the facial and zygomaticotemporal nerves. *J Plast Reconstr Aesthet Surg*. 2012;65:1188–1192.
54. Hwang K, Hwang JH, Cho HJ, Kim DJ, Chung IH. Horizontal branch of the supraorbital nerve and temporal branch of the facial nerve. *J Craniofac Surg*. 2005;16:647–649.
55. Tohma A, Mine K, Tamatsu Y, Shimada K. Communication between the buccal nerve (V) and facial nerve (VII) in the human face. *Ann Anat*. 2004;186:173–178.
56. Monkhouse WS. The anatomy of the facial nerve. *Ear Nose Throat J*. 1990;69:677–683, 686–687.
57. Bernstein L, Nelson RH. Surgical anatomy of the extraparotid distribution of the facial nerve. *Arch Otolaryngol*. 1984;110:177–183.
58. Hwang K, Jin S, Park JH, Kim DJ, Chung IH. Relation of mental nerve with mandibular branch of the facial nerve. *J Craniofac Surg*. 2007;18:165–168.
59. Tansatit T, Phanchart P, Chinnawong D, Apinuntrum P, Phetudom T, Sahraoui YM. A cadaveric study of the communication patterns between the buccal trunks of the facial nerve and the infraorbital nerve in the midface. *J Craniofac Surg*. 2016;27:214–218.
60. Hwang K, Jin S, Park JH, Chung IH. Cutaneous distribution of zygomaticofacial nerve. *J Craniofac Surg*. 2007;18:575–577.
61. Connor NP, Abbs JH. Orofacial proprioception: analyses of cutaneous mechanoreceptor population properties using artificial neural networks. *J Commun Disord*. 1998;31:535–542; 553.
62. Parnes SM, Strominger N, Silver S, Goldstein JC. Alternate innervations of facial musculature. *Arch Otolaryngol*. 1982;108:418–421.
63. Kim L, Byrne PJ. Controversies in contemporary facial reanimation. *Facial Plast Surg Clin North Am*. 2016;24:275–297.
64. Veillon A, Ramos-Taboada L, Abu-Eid M, Charpiot A, Riehm S. Imaging of the facial nerve. *Eur J Radiol*. 2010;74:341–348.
65. Borges A, Casselman J. Imaging the trigeminal nerve. *Eur J Radiol*. 2010;74:323–340.
66. Olson W, Dong P, Fleming M, Luo W. The specification and wiring of mammalian cutaneous low-threshold mechanoreceptors. *WIREs Dev Biol*. 2016;5:389–404.
67. Andreatta RD, Barlow SM. Somatosensory gating is dependent on the rate of force recruitment in the human orofacial system. *J Speech Lang Hear Res*. 2009;52:1566–1578.
68. Del Valle ME, Cobo T, Cobo JL, Vega JA. Mechanosensory neurons, cutaneous mechanoreceptors, and putative mechano-proteins. *Microsc Res Tech*. 2012;75:1033–1043.
69. Cabo R, Alonso P, Viña E, et al. ASIC2 is present in human mechanosensory neurons of the dorsal root ganglia and in mechanoreceptors of the glabrous skin. *Histochem Cell Biol*. 2015;143:267–276.
70. Florez-Paz D, Bali KK, Kuner R, Gomis A. A critical role for Piezo2 channels in the mechanotransduction of mouse proprioceptive neurons. *Sci Rep*. 2016;6:25923.