



Double aortic arch diagnosed in a 44-year-old woman with recurring respiratory infections



Ana Fernández-Tena*, Cristina Martínez-González

University of Oviedo, Hospital Universitario Central de Asturias (HUCA), Avda de Roma s/n, 33011 Oviedo, Spain

ARTICLE INFO

Article history:

Received 29 December 2016

Received in revised form

19 February 2017

Accepted 27 February 2017

Keywords:

Double aortic arch

Vascular ring

Dysphagia

Dyspnea

ABSTRACT

Complete vascular rings are originated because of the persistence of the fourth aortic arches, which surround the trachea and esophagus partially or completely, compressing them. The most common type of complete vascular ring is the double aortic arch. Symptoms usually appear in the first months of life, and are provoked by esophageal and tracheal compression. The diagnosis is usually made through the chest X-ray and the esophagogram in patients with dysphagia. We present a case in which the diagnosis of a double aortic arch was made in adulthood, suspected through a spirometry test and a chest X-ray.

© 2017 The Authors. Published by Elsevier Ltd. This is an open access article under the CC BY-NC-ND license (<http://creativecommons.org/licenses/by-nc-nd/4.0/>).

1. Background

Complete vascular rings are originated because of the persistence of the fourth aortic arches, which surround the trachea and esophagus partially or completely, compressing them. They are rare vascular defects, representing the 0.8%–2% of congenital heart diseases [1]. The term vascular ring not only includes complete rings, but also partial rings with or without fibrous bands or ligaments that also could cause tracheal or esophageal compression. The most common type of complete vascular ring is the double aortic arch, which accounts for 70% of the complete rings [2]. In most cases, there are two permeable arches, usually with right dominance. In rare cases both arches are symmetrical [3].

Symptoms usually appear in the 5th month of life, and they rarely first appear during adulthood [4]. Esophageal compression causes swallowing disorders that usually exacerbate respiratory symptoms as a result of repeated bronchoaspirations. Tracheal compression produces expiratory stridor. If an early diagnosis is not made, respiratory problems may be more pronounced [5]. The diagnosis is usually made through the chest X-ray and the esophagogram in patients with dysphagia. Treatment consists in a surgical division of the vascular ring, cutting and separating the smallest branch of the aortic arch. It is indicated in patients with

symptoms of esophageal or tracheal compression.

2. Case presentation

In May 2012, a 44-year-old woman was referred from primary care for recurrent respiratory infections. She worked as an assistant in a dental clinic, was an ex-smoker of 30 packs/year, and had community-acquired pneumonia (CAP) in left lower lobe in October 2011 and a new episode of CAP in March Of 2012, this time located in lingula. She had not undergone surgery or ever followed any chronic treatment.

The patient reported, from the age of 20, coughing throughout the day, productive of a small amount of yellow sputum. Once or twice a year, also from the age of 20, expectoration increased for 2–3 weeks, requiring antibiotic treatment. The patient also reported grade 1 dyspnea on the mMRC scale, which does not worsen significantly during these episodes. She also referred frequent choking related to the ingestion of spicy or acid foods, sometimes associated to asphyxic crises, consisting in 5–10 seconds with breathing difficulties.

Physical examination was strictly normal.

A spirometry test was performed, which showed a flattening of the expiratory loop in all the performed maneuvers (Fig. 1). With the suspicion of an intrathoracic obstruction, a posteroanterior chest X-ray was made, that showed a narrowing of the tracheal lumen at the aortic arch, which in turn showed an atypical morphology (Fig. 2).

In view of these findings, a thoracic CT was requested, in which a

* Corresponding author.

E-mail addresses: tenaana@uniovi.es (A. Fernández-Tena), cmartinez@hca.es (C. Martínez-González).

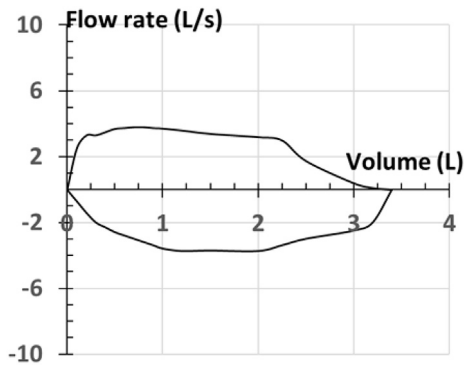


Fig. 1. Spirometry with expiratory loop flattening.

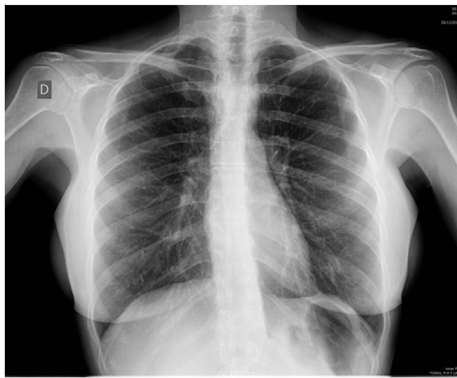


Fig. 2. Posteroanterior thoracic X-ray, observing a narrowing of the tracheal lumen in the aortic button, which shows an atypical morphology.

double aortic arch was found. It completely surrounded the trachea and esophagus (Fig. 3). The left arch had a diameter of 1.3×1.2 cm and the right arch a diameter of 1.9×1.8 cm. The double aortic arch compressed the esophagus and trachea, stenosing for less than 50% their lumen. The supra-aortic trunks had a normal caliber. There was an independent origin of the two right trunks from the right aortic arch and the two left trunks from the left aortic arch.

To check if there was a compromise of the tracheal lumen, a bronchoscopy was performed, which showed the presence of an

extrinsic stenosis of approximately 20% of the tracheal lumen at 4 cm of the main carina, associated with moderate tracheomalacia.

The patient was referred to the Digestive Service to assess the esophageal involvement. An esophagogram was performed, observing the presence of extrinsic compressions with two esophageal imprints related to each aortic button. Subsequently, a gastroscopy was performed confirming those findings (Fig. 4).

Finally, the patient was referred to the Vascular Surgery Service, who explained her the possibility of a surgical resection of the smaller aortic arch. The patient refused surgery despite presenting symptoms with increasing frequency (since 2010 she started having 3–4 respiratory infections each year). Nowadays she is attending to biannual dates with Vascular Surgery Service, and still doesn't want to undergo surgery.

3. Discussion

Complete vascular rings occur early in embryologic development. They result from the abnormal regression of the embryonic branchial arches. The most common type of complete vascular ring is the double aortic arch, which accounts for 70% of the complete rings [2].

Double aortic arch appears when the involution of the distal right fourth arch does not take place. The fourth right and left arches persist and join the descending thoracic aorta. Both arches surround the trachea and esophagus, compressing them. Tracheoesophageal compression typically results in early symptoms.

The double aortic arch usually occurs as an isolated lesion. However, in approximately 22% of the cases, it may be associated with other congenital heart diseases, such as interventricular communication, tetralogy of Fallot, transposition of the great vessels or the common truncus arteriosus. It also can be associated to some genetic syndromes, as the deletion of the short arm of chromosome 22 [6].

Symptoms usually appear during the first weeks of life. The usual age of presentation is 5 months of life. The symptoms are mainly respiratory, because of the tracheal compression. Esophageal compression causes swallowing disorders manifested as vomiting or food intolerance, and they usually exacerbate respiratory symptoms as a result of repeated bronchoaspirations. If an early diagnosis is not made, respiratory problems, mainly frequent respiratory infections, may be more pronounced, especially if there is some degree of malacia associated [5]. Adult presentations of

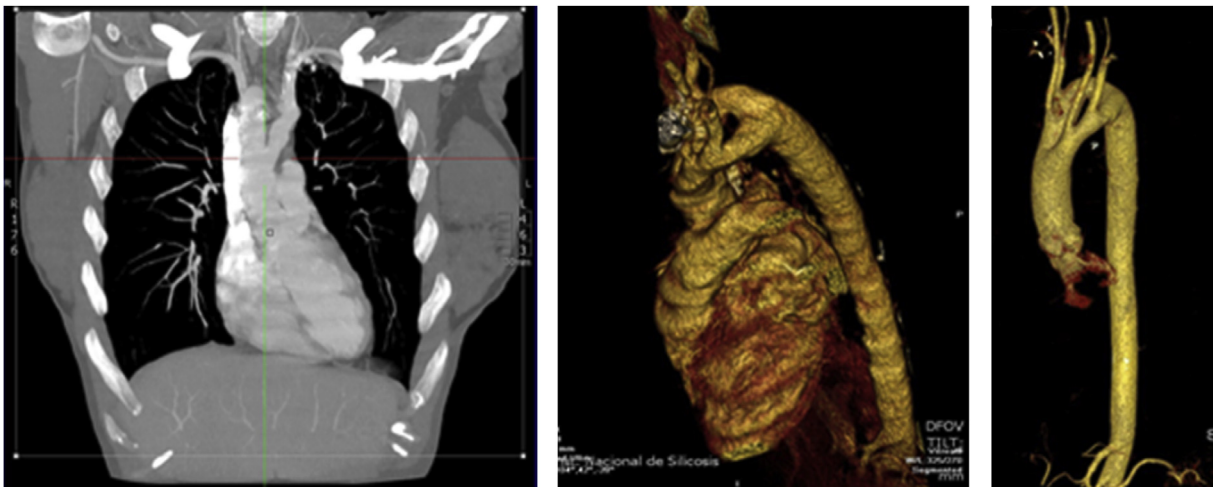


Fig. 3. The thoracic CT showed the presence of a double aortic arch that completely surrounded the trachea and the esophagus, conditioning a stenosis of less than 50%.

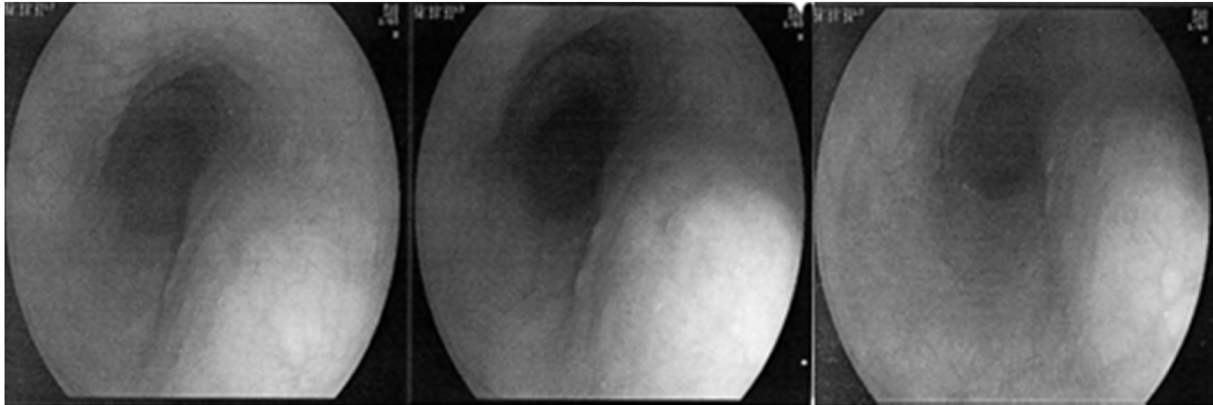


Fig. 4. Pictures taken during the gastroscopy, which showed the imprints produced by both aortic arches on the esophagus.

vascular rings are exceptionally rare, and dyspnea on exertion is the most common symptom [7].

Complementary tests play a major role in the diagnosis of this malformation. The most important non-invasive study for the diagnosis is usually the esophagogram, which shows left and right notches in the esophagus. The chest X-ray usually shows a compression of the trachea. The interesting thing about this case is that the symptomatology of the patient went unnoticed until adulthood. A stenosis of the endotracheal airway was suspected due to a routine spirometry test, which showed a flattening of the expiratory loop.

Surgical division of the vascular ring is indicated in patients with symptoms of esophageal or tracheal compression. The long-term prognosis is excellent [8]. Surgery involves cutting and separating one of the branches of the aortic arch, usually the smallest one, suturing one end into the subclavian artery and the other end at the point where it is inserted into the descending aorta [9]. Our patient refused surgery, and a close surveillance was decided. It remains unclear in literature which is the best treatment option in adult people who can't go under surgery [7].

4. Conclusions

The double aortic arch is a rare congenital anomaly, which should be suspected in patients with recurrent respiratory infections and/or with dysphagia. The ideal treatment is surgical repair.

Declaration of interest

The authors declare that no conflicts of interest exist. The authors alone are responsible for the content and writing of the paper.

Acknowledgements

The authors gratefully acknowledge the financial support provided by Sociedad Asturiana de Patología Respiratoria (ASTURPAR) and Fundación AIRE under project “Experimental and numerical study of a three-dimensional model of an asthmatic patient airways reconstructed from CT or MR images”.

References

- [1] S.C. Park, J.R. Zuberbuhler, Vascular ring and pulmonary sling, in: R.H. Anderson, E.J. Baker, R.F. Macartney, M.L. Rigby, E.A. Shinerbourne, M. Tynan (Eds.), *Paediatric Cardiology*, second ed., London Harcourt Publishers, 2002, pp. 1559–1575.
- [2] Girona Comas J: Anillos y slings vasculares. Protocolos diagnosticos y terapeuticos en Cardiología Pediatrica, Servicio de Cardiología Pediatrica, Hospital Universitario Vall d'Hebron, Barcelona.
- [3] C.L. Backer, Vascular rings, slings and tracheal rings, *Mayo Clin. Proc.* 68 (1993) 1131–1133.
- [4] K. Kanabuchi, N. Noguchi, T. Kondo, Vascular tracheobronchial compression syndrome in adults: a review, *Tokai J. Exp. Clin. Med.* 36 (4) (2011 Dec 20) 106–111.
- [5] A. Vázquez-Antona Clara, Luis Muñoz-Castellanos, Magda Kuri-Nivón, Jesús Vargas-Barrón, Anillo vascular por doble arco aórtico simétrico. Reporte de un caso, *Arch. Cardiol. Méx* 75 (2) (2005) 178–181 [Internet]. Abr [cited 2016 Dic 29]. Available at, http://www.scielo.org.mx/scielo.php?script=sci_arttext&pid=S1405-99402005000200009&lng=es.
- [6] D.B. McElhinney, B.J. Clark, P.M. Weinberg, M.L. Kenton, D. McDonald-McGinn, D.A. Driscoll, et al., Association of chromosome 22q11 deletion with isolated anomalies of aortic arch laterality and branching, *J. Am. Coll. Cardiol.* 37 (2001) 2114–2119.
- [7] C. Ryu, J. Puchalski, M. Perkins, S. Honiden, Management of an elderly patient with respiratory failure due to double aortic arch, *Respir. Med. Case Rep.* 17 (2015 Dec 17) 37–39.
- [8] G. Shanmugam, K. Macarthur, J. Pollock, Surgical repair of double aortic arch: 16-year experience, *Asian Cardiovasc Thorac. Ann.* 13 (1) (2005) 4–10.
- [9] S. Talwar, R. Sharma, S. Agarwal, S. Sharma, et al., Innominate artery compression of trachea: treatable airway obstruction, *Asian Cardiovasc Thorac. Ann.* 8 (2000) 391–393.